

Anterior missing teeth and growth

Edited by Prof. Aris Petros Tripodakis

Dr Frank Bonnet

Scientific Chairman's Introduction

One of the most challenging situations encountered in dental practice today is the case of anterior missing teeth in relation to growth. Craniofacial growth in adolescents and young adults and ongoing continuous alveolar growth on the other, create an unstable ground for a long lasting successful restorative outcome. The limits on the decision-making process in generating a comprehensive treatment plan, are dictated by the practitioner's specialty, educational background and clinical habits of treatment. It is obvious that there is a need for a multidisciplinary analysis and approach that provides the advice and direction toward the series of the combined and properly coordinated successful therapeutic options.

At first the decision-making process is questioned on whether to orthodontically close the space of the missing tooth, or preserve the edentulous space for tooth replacement. It has been well established in the literature that this decision is mainly related and dependent on the craniofacial classification of the patient. On the other hand, orthodontic edentulous space closure has also been advocated, irrespectively to the craniofacial classification. An actual debate between the two options therefore, will have to take into consideration the potential clinical outcome on the basis of both dental and facial Esthetics.

If preservation of the edentulous space for tooth replacement is decided, the restorative versus the implant solution present the two possible options. The common goal would be to replace the missing tooth while the tooth structure of the adjacent teeth is not compromised. Adhesive restorative dentistry can provide restorative compensation and substitution of teeth into homologous teeth in combination with minor orthodontic interventions such as distributing or shifting the gap. If opening the gap for an adhesive FPD is decided, pontic-site development procedures concerning the hard and soft tissue parameters should also be taken under consideration along with the long-term retention and stability of the adhesive bridge.

The implant treatment for the replacement of the missing tooth still enjoys great popularity. Growth however can pose a medium- or long-term problem to the implant restoration by maintaining its ankylosed position in an environment in which adjacent teeth can shift or erupt. Adolescence craniofacial growth on one hand, on-going alveolar growth and continuous tooth eruption on the other, are the risk factors potentially jeopardizing the long-term esthetic outcome.

Session I

The anterior missing tooth and Orthodontics in the growing patient: Open or Close?

Moderator: Prof. Marinello Carlo

Session's Introduction

There is an empirical saying that if as a prosthodontist you have a good orthodontist aside, every case will also be an orthodontic case. If however, no orthodontist is available, every case can be solved alone with prosthodontic means. Of course, the same is true vice-versa: *"What to do when you do not have a good prosthodontist to work with on your case"* (Johal et al. 2013). The challenging theme in the title is reflecting this clinical dilemma.

Although long-term studies comparing directly the many relevant treatment options are lacking and although there is still a lack of good quality evidence regarding the best approach, a meticulous multi- and interdisciplinary diagnosis and treatment planning remains imperative to define "the best strategy" that will provide the optimal individual result for our patients (Silveira et al. 2016). It is the aim of the workshop to present a comprehensive and in the daily practice applicable overview of the diagnostic means leading to a targeted decision-making process and concrete clinical solutions.

The onward aging of our patients, the associated demand for minimal-invasive dentistry that is based on reversibility and ease of reintervention, the long-term experiences with many cases, but also the inclusion of new factors (3D radiographic diagnostics, better understanding of facial growth and aging, easier movement of teeth (corticotomy-facilitated orthodontics), should lead to new considerations in the treatment of the anterior missing tooth in the growing patient.

Today, based on a thorough diagnostic evaluation of a specific case, orthodontists are technically able in most instances to symmetrically or asymmetrically close gaps in the frontal region, by this eliminating the need for any tooth replacement. In this case, the prosthodontist is needed at most for minor esthetic alterations such as bleaching, odontoplasty, composite addition, veneer or single crown placement (Rosa et al. 2016). This strategy, beside the advantage to be a straight forward solution for the dentist and the patient, may provoke several general esthetic and functional questions: Is it a physiologic situation, what impact does it have on the dental arch, is the dental arch smaller, is it v-shaped instead of u-shaped, is it leading to an open buccal corridor, what about soft tissue support, does it reduce the space for the tongue, does it need a life-long retention with all the consequences this may have, what is the impact on overjet, overbite and the vertical dimension of occlusion, what is the impact on the mandible and, what about potential risks of orthodontic therapy in general?

If at all tooth replacement is considered, the gap may be brought to the posterior, esthetically less demanding region of the dental arch. In this case, a compromise closing the gap prosthetically may be found more easily (Kokich et al. 2011). However, specific questions concerning long-term behavior remain: what happens functionally to a first premolar in the canine position, what are the orthodontic, functional, esthetic and biologic consequences of a canine in the position of a lateral incisor, or of a lateral incisor in the position of a central incisor?

The other strategy, to place the teeth at their original position and to specifically replace the missing tooth locally by several prosthodontic options (2-unit cantilever resin-bonded fixed partial denture, implant-supported single crown, conventional 2-unit cantilever fixed partial denture, conventional 3-unit fixed partial denture, single veneer / crown on a autotransplanted tooth) sounds logic, reasonable and mostly desirable. However, beside the advantage to keep the dental arch in a complete physiologic form, the several initially successful "prosthetic solutions" in the long-term may be compromised by possible biologic and esthetic consequences such as additional growth, maturation, adaptation and aging, beside all the inherent risks of the restoration itself.

Whatever direction is chosen, the in-depth understanding of the lifelong craniofacial growth/maturation with significant individual variation and its implications for implant placement as well as the professional esthetic, functional and biologic management of the alveolar ridge in both, the vertical and horizontal dimension is indispensable (Oesterle & Cronin 2000, Daftary et al. 2012, Urban et al. 2019).

It is the aim of the orthodontic lectures **i)** to display all the relevant diagnostic aspects that have an impact on the decision making process of closing and opening the gap in the maxillary front region with a missing tooth, **ii)** to present the advantages and disadvantages that opening and closing gaps may have during and after the treatment in the long-term (including cost-effectiveness), **iii)** to judge and value the "prosthetic solutions" from the orthodontist's point of view, and last but not least **iv)** to include the factor growth in all the careful considerations.

REFERENCES

1. Daftary F, Mahallati R, Bahat O, Sullivan RM. Lifelong craniofacial growth and the implications for osseointegrated implants. *Int J Oral Maxillofac Implants*. 2013 Jan-Feb;28(1):163-9
2. Johal A, Katsaros C, Kuijpers-Jagtman AM. State of the science on controversial topics: missing maxillary lateral incisors—a report of the Angle Society of Europe 2012 meeting. *Prog Orthod*. 2013 Jul 26;14:20
3. Kokich VO Jr, Kinzer GA, Janakievski J. Congenitally missing maxillary lateral incisors: Restorative replacement. *Am J Orthod Dentofacial Orthop*. 2011 Apr;139(4):435-445.
4. Oesterle LJ, Cronin RJ. Adult growth, aging, and the single-tooth implant. *Int J Oral Maxillofac Implants*. 2000 Mar- Apr;15(2):252-60.
5. Rosa M, Lucchi P, Ferrari S, Zachrisson BU, Caprioglio A. Congenitally missing maxillary lateral incisors: Long-term periodontal and functional evaluation after orthodontic space closure with first premolar intrusion and canine extrusion. *Am J Orthod Dentofacial Orthop*. 2016 Mar;149(3):339-48.
6. Silveira GS, de Almeida NV, Pereira DM, Mattos CT, Mucha JN. Prosthetic replacement vs space closure for maxillary lateral incisor agenesis: A systematic review. *Am J Orthod Dentofacial Orthop*. 2016 Aug;150(2):228-37.

Essayist I

Dr. Marco Rosa:

Orthodontic edentulous space elimination. Space closure irrespectively the craniofacial classification. Outcome evaluation of facial and dental esthetics.

Introduction

Even if the advent of the osseointegrated implants reduced the popularity of the "space closure" alternative, still there are at least 3 major reasons to consider the space closure alternative the most interesting:

1. From a biologic, esthetic and periodontal perspective, a tooth or a root is almost always better than a "foreign body" and the possible negative side-effects during life are minimum. Even more so, in the esthetic zone where the management of the "transition zone", between white and pink tissues, means an ideal balance of health & esthetics.
2. Considering that in the vast majority of the cases an orthodontic treatment is anyhow necessary, the overall treatment time is shorter and the cost-benefit ratio is better. This is for crucial interest when treating growing patients and young adults.
3. "Space closure" is nowadays an evidence-based, long-term-effective, treatment¹⁻⁷. The available scientific evidence demonstrated that, in the long-term, space closure:
 1. produces results well accepted by patient;
 2. does not impair TMJ function;
 3. encourages periodontal health.

Nordquist and McNeil compared Mean 10 years post-treatment 39 space closure to 19 space opening and prosthetic replacement (13 bridge, 6 removable plate). They concluded that:

- 1) space closure patients are healthier periodontally than prosthesis patients;
- 2) there is no difference in occlusal function;
- 3) presence or absence of canine rise is not related to periodontal status;
- 4) No evidence that CII canine relation is the preferred mode of treatment.¹

Thordarson et al demonstrated that ground canines are stable and safe Long-term (mean >10 yrs).² Robertsson and Mohlin investigated 50 adult patients mean 7 yrs post-op (30 space closure vs 20 space opening and prosthetic replacement) and demonstrated

- 1) that space closure patients were more satisfied than prosthesis patients;
- 2) there is no difference in the presence of TMD;
- 3) Prosthesis patients have more plaque and gingivitis.³

Czochrowska et al investigated 23 pts the substitution of a missing maxillary central incisor with the lateral incisor comparing the space closure site to the contra-lateral central incisor mean 6 years post-treatment. They reported similar position and appearance, no detrimental effects on Rx and concluded that "the substitution of a central incisor with the lateral is a valid treatment modality, if the indications for such treatment are present and careful attention to detail in orthodontic and restorative treatment is exercised"⁴.

Jamilian et al compared the periodontal and esthetic outcome of 17 space closure sites and 14 implants mean 6 years post-op. They reported similar, well-accepted esthetic results, NO TMD, evident infra-occlusion in the implant patients and concluded that space closure patients have a better periodontal health⁵.

Rosa et al demonstrated that space closure including *first premolar intrusion* and *canine extrusion* in patients with missing lateral incisors does not incur a risk for periodontal tissue deterioration nor TMD problems in the long term (mean 10 years post-op)⁶.

Josefsson and Lindsten compared the clinical and esthetic outcome of 28 single-implant restoration to 38 space closure sites 5 years after treatment and concluded that, "if both treatment alternatives are available, space closure is preferable"⁷.

Besides, a recent literature systematic review confirmed that the lateral occlusion scheme has minimal impact on the patient comfort and biology or mechanical complication. Canine guidance and group function are equally acceptable.⁸

If health and function are not under discussion since 1975, then, at the end of the last century, esthetics became a major focus also for the orthodontists. After space closure, the main esthetic problems were

the tendency of the spaces to re-open and the overall not natural looking of the smile: even if properly ground, the canine is yellowish, the first premolar is too small and the periodontal profile is not normal. At the same time the first doubts about the implant solution began to arise. Thus it was proposed a new method to improve the esthetic outcome and finalize at the best the orthodontic treatment after the space closure and the correction of the malocclusion.⁹⁻¹² The main points are:

1. Extrusion and intrusion movements of the front teeth to create a correct leveling of the gingival margins.
2. Precise torque control during extrusion and intrusion to keep the roots into the dento-alveolar envelope.
3. Minor restoration and vital leaching of the yellowish extruded canine moved in the place of the lateral incisor.
4. Restorations on the intruded first premolar to let it resemble and work as a canine.
5. Restoration of the central incisors not only when the lateral incisor is substituting a central,⁴ but also in the patients with congenitally missing lateral incisors (CMLI), because they have small teeth¹³⁻¹⁸.

These improvements introduced a significant change in how to approach the treatment of missing teeth in the esthetic zone: no longer a mere "canine substitution", but an interdisciplinary treatment looking for excellence. The orthodontic treatment is the first fundamental phase, with the aim not only of closing the spaces and correcting the malocclusion, but also creating the anatomic conditions (roots and periodontal tissues) to allow the dentist perform minimally invasive restorations on the front teeth.

Space closure irrespectively the craniofacial classification.

Traditionally, the "space closure" alternative is indicated in the Class II malocclusions, in case of lower crowding and incisors' protrusion, while the main esthetic procedure is the grinding of the canine to let it resemble a lateral incisor. On the other hand, "space closure" would be contra-indicated in the Class III malocclusions, in patients with a short face / concave profile and in the patients with canines of big size.

Nowadays, by combining carefully detailed orthodontic, periodontal and reconstructive procedures, it is possible to "close the spaces" and achieve a functionally and esthetically satisfactory, long term stable outcome in all malocclusions^{9-12,19}.

Active treatment is planned in three steps:

1. Space closure and correction of the malocclusion.
2. Orthodontic finishing in the esthetic zone.
3. Minimally (or NO) invasive restorations on the front teeth.

Space closure should be performed with fixed appliances.

This stage of the treatment is usually easier when extractions in the lower arch are indicated. Nevertheless, if patient's compliance is good, it is possible to close the upper spaces also when lower extractions are not indicated and it is not allowed to distally move the upper incisors (maximum anchorage on upper front teeth), by using as an anchorage class III elastics supported by appliances in the lower arch^{9,10}.

Upper space closure is nowadays not only possible, but also faster and predictable (without cooperation) in a short active treatment time (10-14 months) by using a skeletal anchorage¹⁹⁻²¹. Two temporary anchorage devices (TADs) placed in the palate are sufficient and effective to support a sliding mechanic which moves mesially all posterior teeth. This system doesn't require the lower arch and class III elastics as an additional anchorage. The skeletal anchorage also allows to close the space unilaterally with no cooperation in patients with a normal occlusion (a contra-indicated "mission impossible" before the introduction of the skeletal anchorage).

In case of severe skeletal discrepancy, the orthodontic space closure in the context of a surgical approach is indicated to correct the malocclusion, while creating the correct structural frame for an ideally displaced smile and face¹¹.

Orthodontic finishing.

In the esthetic zone treatment starts with a detailed diagnosis, treatment plan and positioning of the braces²². The goal is to place the anterior teeth in a way that minimally, or no-invasive restorations can be made not only to compensate the anatomic variations, but also to give added value to what can be achieved with orthodontic treatment only.

Orthodontic finishing is crucial in the patients who show the gingival margins. The starting point is the position of the upper incisors: the upper midline should be placed on the philtrum of the upper lip the long axis of the central incisors must be parallel to the long axis of the face, irrespectively to the lower midline (in case of mandibular asymmetry). The vertical display of the maxillary incisors should be planned

not only on the upper lip at rest, but also considering the smile line and the relation between the gingival margins and the upper lip during conversation and smile. The gingival margins should be visible according to the skeletal pattern, age and sex²³.

The smile line and gingival profile should be adjusted orthodontically by means of canine's extrusion and first premolar's intrusion. The lateral incisor moved in the place of the central has to be intruded, until the CEJ is at the same level of the contra-lateral central incisor. Following the intrusion/extrusion movements of the adjacent teeth, uneven bone peaks will become evident radiologically at the contact point ("radiological vertical defect"). The vertical movements are effective in remodeling the periodontal profile and don't interfere with health. The patient can brush and floss effectively, thus adding long term periodontal health of the intruded first premolars, which is evidence based⁶.

It is crucial to keep the roots inside the dento-alveolar envelope by a precise torque control especially in case of thin periodontal biotype. To prevent a possible space reopening the roots should be placed with a distal angulation of 5 to 10°. The mesio-distal stripping and palatal grinding of the canine²⁴, should be finalized during the orthodontic finishing phase.

Orthodontic finishing is strictly correlated to the restorative phase of the interdisciplinary treatment, thus the orthodontist should take all decisions together with the prosthodontist and the periodontist.

Minimally (or not) invasive restorations.

Such restorations are necessary on all the front teeth when the goal is esthetic excellence, precise anterior guidance and better long term stability. Beyond the mere grinding of the canine to let it resemble a lateral incisor, multiple restorations are often indicated to compensate for the anatomical discrepancies of the front teeth: in length, width and thickness.

Outcome evaluation of facial esthetics.

The esthetic benefits on smile and profile are among the main goals of orthodontic treatment. Do extractions necessarily result in a flat face and narrow smiles? No, when properly indicated extraction are fundamental to improve the profile²⁵⁻²⁷, the smile²⁸⁻³², promote periodontal health^{33,34}, and long term stability^{34,35}. Although tooth extractions seem to influence facial esthetics, existing studies are heterogenous and no consistent predictions of profile, smile response and cumulative effect of aging can be made²⁸. The success of orthodontic treatment depends on the careful analysis of all diagnostic elements and establishment of a correct treatment planning.

There is a bias that in patients with missing maxillary incisors, *where an extraction protocol is not indicated*, space closure should be avoided because they may impair the facial profile and produce "narrow" smile. Conversely, in front of a concave profile, it would be better to open the spaces in order to improve the posture of the lips, the profile and provide a "wider" smile. This is a very superficial way to approach the issue. Actually, space closure could affect the facial esthetics in both areas: the profile and the smile width, but important details are to be briefly underlined.

Space Closure and Profile.

A widespread opinion is that the A/P position of the incisor crowns is the main focus when planning the changes of the soft tissues profile, i.e. buccal tip of the upper incisors in Class III, concave profile and palatal tip / overjet correction in Class II.

At the end of any orthodontic treatment, when occlusion is normal, lips are resting on the crown of the upper incisors. Thus, if overjet is normal, what makes the *profile* more or less convex/concave, is the position of the lower incisors and their relationship to the chin (Pogonion and Menton): skeletal pattern, vertical dimension as well as the anatomy and position of the symphysis.

In the absence of surgical procedures, the orthodontic treatment can tip the incisors at any age, while the position of the chin can be affected mainly during growth by the vertical control of posterior teeth.

In a Class III tendency, short face, concave profile, if overjet is normal space opening and prosthetic replacement of the missing incisors is irrelevant for the profile and lip posture. If overjet is negative before treatment and can be corrected by a labial tip of the upper incisors, the improvement is not relevant¹¹. In the short faces, concave profile, a possible slight extrusion of the molars with consequent post rotation of the mandibular plane will increase in the vertical dimension and the profile's convexity, as well as allow some extrusion of the upper front teeth. The increase of the vertical dimension, if possible, is much more effective than the buccal tip of the upper incisors¹⁰.

On the contrary, in case of skeletal Class II with convex profile, the main goal is to prevent an excessive dento-alveolar compensation produced by the palatal tip of the upper incisors looking for the orthodontic overjet correction. Skeletally, any posterior distalization and expansion procedure in the lower arch shouldn't be planned to prevent an increase of the anterior facial height and mandibular post-rotation. Both, upper incisors' palatal tip and mandibular post rotation could produce an evident decline of the profile and worsening of the lips posture. Thus, in case of convex profile and retruded mandible, when the upper incisors are well uprighted, it is better to leave some overjet between the palatal surfaces of the upper incisors and the incisal edges of the lower front teeth. This gap is to be filled by the restorations¹¹.

Space Closure and Smile Width

Orthodontic treatment affects the esthetics of the smile in the three dimensions. The existing data evidenced that, if orthodontic treatment has been carried out with thorough diagnosis and careful planning, the choice of extraction treatment, not necessarily is resulting in buccal corridor and affect negatively the frontal facial attractiveness²⁸⁻³¹. Conversely non-extraction orthodontic treatment by means of broadening the anterior sweep of the maxillary arch and increasing of upper teeth buccal tip, might flatten the smile arc, reduce the incisor display and make the smile less youthful and attractive²⁹. Thus once again, in case of missing maxillary incisors, it is not the space-opening alternative which will improve the smile esthetics. If we "expand", it could be the opposite.

If we want to improve the face esthetics and put the smile in the foreground, we should upright the upper teeth into the dento-alveolar envelope, reduce the arch depth (A/P position) of the whole maxilla, increase the vertical display of the upper front teeth and reduce the vertical exposure of the lower incisors and canines. All these goals can be achieved by the orthodontic treatment alone, (Fig. 1&2) if 2-4 mm is enough¹⁰, or combined to the surgical maxillary downgraft and/or advancement^{11,30}.

When the goal is a full smile, the most challenging malocclusions to handle are:

1. the skeletal class II with retruded mandible, while the maxillary arch is in good occlusion;
2. the maxillary vertical deficiency and patients who don't show the upper gingival margins.

In front of these patients, orthodontics and/or prosthetic rehabilitation are not capable to provide adequate treatment. In the case of a growing, young patient showing this features, orthodontic space closure in the context of a surgical approach could be one of the best investment in life¹¹.

Outcome evaluation of dental esthetics.

After the orthodontic space closure, the esthetics of the upper front teeth is of course wrong: first premolars are smaller than the canines, canines are not lateral incisors and lateral incisors are much different than the centrals. Besides the periodontal profile is not correct: the gingival margins of the canines are higher than the central incisors, while the first premolars are too short and their gingival margins at a lower level. In the absence of orthodontic periodontal profile's adjustment and cosmetic restorations to compensate for the limitations of orthodontic treatment, it is impossible to obtain an ideal esthetic and functional result. This point becomes clinically relevant when a significant difference in size and color is evident among the canines and incisors.

Nevertheless, if we look at the scientific evidence, in case of congenitally missing maxillary lateral incisors (CMLI) the final esthetic outcome could be acceptable even with no restorations and orthodontic remodeling of the periodontal profile. There is some evidence that lay people don't see all the esthetic details that in the opinion of the professionals (dentists, orthodontists, prosthodontists), are noticeable^{36,37} and that the mere space closure is evaluated better esthetically than the prosthetic replacements^{38,39}.

Another point on which there is a general agreement is that interdental spaces (black holes) and a >2 mm discrepancy in incisor crown angulation are considered the worst⁴⁰⁻⁴². Asymmetric alterations of the gingival exposure, occlusal plane's cant and crown width seem to be more acceptable, being the threshold of recognition by the laypeople beyond 4.0 mm⁴²⁻⁴³. The size of teeth is a crucial issue too. Previous researchers demonstrated in patients with multiple congenitally missing teeth that a close relationship exists between the degree of agenesis and the reduction in tooth width⁴⁴⁻⁴⁶. One relevant recent finding is that subjects with congenitally missing maxillary lateral incisors as a single dental anomaly, have smaller teeth when compared to those with a normal dentition¹³⁻¹⁸, while sometimes there are differences in size and shape between the R/L incisors. Clinical inferences about tooth esthetics can be withdrawn.

Small teeth (central incisors too) should be recognized before treatment, in the diagnostic phase. In front of a patient who shows "big canines" the first question should be: "are the canines large or are the teeth and the central incisors small? perhaps the central incisors are small and the canines are almost perfect

in size to substitute the lateral incisors in that face". The clinical art of seeing more than the scientific evidence^{47,48}, is fundamental in this phase.

The patient has to be informed that, if teeth are small, some side effects are very likely to become noticeable after orthodontic treatment:

1. reopening of the spaces and embrasures in case of space closure;
2. not adequate space for the implant in case of orthodontic implant site development;
3. inadequate vertical display of the central incisors and smile arc;
4. some overjet palatally to the maxillary central incisors;
5. not natural looking and balanced smile.

Yellowish canine is to be ground palatally, mesially and distally²⁴, during the orthodontic finishing phase. The labial surface is to be ground (flattened) after the torque correction: when the root is properly placed in the alveolar bone, the canine can be ground mainly in the incisal half, where the enamel is thicker. Small direct restorations are often necessary to fill the black triangle and embrasure mesially on the canine. If the vital bleaching of the yellowish canine is planned, then a more whitish colored composite is to be used so that the vital bleaching will adapt to the white composite and not vice-versa⁹.

A common mistake during the extrusion of the canine with labial appliances is the buccal root torque, consequent thinning of the buccal cortical plate and some risk to favor the development of recessions⁵¹. This side effect must be prevented by a detailed orthodontic palatal root control during extrusion.

Intruded first premolar doesn't need to be ground on the palatal cusp, while it is to be restored in length (new buccal cusp and fossa) and sometimes mesio-distally, when contact points are absent. The restoration will provide proper esthetics (canine should be evident in its vertical display when smiling) and guiding surfaces on the palatal side⁹⁻¹².

A common mistake during the intrusion of the first premolar with labial mechanics, is the buccal tip of the crown, resulting to an evident excessive overjet in the canine area. This will cause great difficulties to the dentist in performing the restoration and change the crown's morphology of the intruded premolar into a canine.

Central incisors are often to be build up¹⁰, because congenitally missing maxillary lateral incisors subjects have small teeth¹³⁻¹⁸, and sometimes the central incisors are different in size and morphology. The central incisors are to be build-up, not only in width, but also in length in order to obtain a correct smile arc and thickness.

In the Class II malocclusions, some overjet could persist at the end of the orthodontic treatment on the well aligned central incisors. In other words, the palatal surfaces of the central incisors not being in contact to the lower incisors. This overjet/gap is to be corrected by the restoration of the central incisors also on the palatal side. The orthodontic correction of the overjet by a further distalization of the central incisor's crown would be a mistake, resulting in a "narrow retruded smile" with small teeth and a major risk of relapse (space reopening).

Conversely, in Class III malocclusions, it is better to correct the overjet orthodontically and the restoration will preferably increase the volume of the small incisors on the buccal side.

When a lateral incisor is moved to the place of the central, all aspects described above become even more difficult to manage. In any case, the lateral incisor should be intruded until the CEJ is at the level of the contra-lateral normal central incisor. This will allow the prosthodontist to place the limit of the restoration at the level of maximum circumference and reduce the unavoidable under-square between root and crown. To reduce the risk of a "black triangle", the root should be placed more/less angulated and close to the adjacent incisors, considering the periodontal biotype, the smile line and the possible reaction of the soft tissue to the planned restoration.

Extraction of the contra-lateral peg-shaped lateral incisor is often better than a unilateral space closure, because the symmetry of the front teeth is easier to be achieved.

How many restorations should be planned to achieve appropriate mesio-distal dimensions and optimal esthetics?

The space closure in the smile area will result in a tooth-size discrepancy in many cases. An appropriate and individualized interdisciplinary treatment plan is recommended after a detailed evaluation of all the

diagnostic tools. Above all the treatment of malocclusion, the correction of the smile line and the patient's expectations should be met.

Soft tissue reaction to orthodontic intrusion and extrusion cannot be easily predicted in detail. If the periodontal support is intact, the soft tissues (gingival margin) follow the vertical movements 60-80% during intrusion^{49,50}, and 90% during extrusion⁵¹. There is a wide individual variation in the behavior of the soft tissue: the main difference is between adolescents and adults. In the adolescents some hypertrophy of the marginal gingiva can be expected due to poor hygiene. The altered passive or active eruption could jeopardize the response of the gingival margins to the vertical orthodontic movements, thus orthodontist should focus also on location of the CEJ. In a limited number of patients, a gingivectomy (and rare respective surgery) is necessary to remodel the soft and hard tissue¹². Patients with compromised periodontal breakdown and attachment loss are expected to react in a different way^{51,52}.

Orthodontic finishing must be planned with the dentist (perio/prostho). According to the established occlusion requirements (overjet/overbite/anterior guidance) and esthetics (exposure of the front teeth and smile arc), the orthodontist and the prosthodontist have to plan and adjust individually the size and position of the front teeth. The procedure to be considered and eventually planned in detail are:

- mesio-distal stripping and palatal grinding of the canine's crown²⁵, while its buccal surface is usually ground after the removal of the fixed appliances, in the context of the cosmetic restorations;
- stripping of the lower incisors;
- whether to leave some interproximal space (in case of small teeth);
- whether to leave some overjet between the palatal surface of the well aligned central incisors and the incisal edges of the lower incisors.

Timing of restorations (from composite to PLV) > stability is crucial for the success of the interdisciplinary treatment. Composite direct⁹⁻¹², or semi-direct⁵³, restorations should be done immediately after the orthodontic appliance removal, together with the retention (fixed and/or removable). After 12-24 months, settling of the occlusion, eventual minor adjustments of the restorations and at least 6 months out of upper retention, the "porcelain/definitive/expensive" restorations could be planned and performed. A group function is the preferable mode of occlusal finishing on anterior teeth^{11,12}. An eventual further removable retention could be planned with the orthodontist.

Conclusions

- The care of patients with congenitally missing lateral incisors is best achieved through a multi-disciplinary detailed approach.
- Space closure is an evidence-based-long-term effective treatment.
- The space closure allows to finish treatment immediately after orthodontics in the growing patients.
- The space closure compared to the prosthetic substitution results to a more predictable long-term periodontal health.
- Patients with congenitally missing incisors most likely have small teeth (also the central incisors).
- The space closure should be the preferred in the growing patients, young adults and when the gingival margins are visible.
- Nowadays, space closure is possible in all malocclusions.
- Space closure under certain conditions doesn't worsen the profile and the smile width.
- In case of space closure, all 6 anterior teeth could be involved in the restorative treatment.
- Direct no-prep composite restorations could be a valid restorative option.

References

1. Nordquist GG, McNeill RW.
Orthodontic vs. restorative treatment of the congenitally absent lateral Incisor – long term periodontal and occlusal evaluation.
Periodontol 1975;46:139-43.
2. Thordarson A, Zachrisson BU, Mjör IA.
Remodeling of canines to the shape of lateral incisors by grinding: A long-term clinical and radiographic evaluation.
Am J Orthod Dentofac Orthop 1991;100:123-32.
3. Robertsson S, Mohlin B.
The congenitally missing upper lateral incisor. A retrospective study of orthodontic space closure versus restorative treatment.
Eur J Orthod 2000;22:697-710.

4. Czochrowska EM, Skaare AB, Stenvik AR, Zachrisson BU.
Outcome of Orthodontic Space Closure with a Missing Maxillary Central Incisor.
Am J Orthod Dentofacial Orthop 2003;123:597-603.
5. Jamilian A, Perillo L, Rosa M.
Missing upper incisors: a retrospective study of orthodontic space closure vs implant.
Progress in Orthodontics 2015;16:2-8.
6. Rosa M, Lucchi P, Ferrari S, Caprioglio A, Zachrisson BU.
Long-term periodontal evaluation in patients with congenitally missing maxillary lateral incisors (CMLI) treated by space closure, canine extrusion and first premolar intrusion.
Am J Orthod Dentofac Orthod 2016;149:339-48.
7. Josefsson E, Lindsten R.
Treatment of missing maxillary lateral incisors: a clinical and aesthetic evaluation.
Eur J Orthod 2019,41/3, June 2019, Pages 273–278.
8. Abduo J, Tennant M.
Impact of lateral occlusion schemes: A systematic review.
J Prosthet Dent. 2015 Aug;114(2):193-204.
9. Rosa M, Zachrisson BU.
Integrating esthetic dentistry and space closure in patients with missing maxillary lateral incisors.
J Clin Orthod. 2001;35(4):221-234.
10. Rosa M, Zachrisson BU.
Integrating Space Closure and Esthetic Dentistry in Patients with Missing Maxillary Lateral Incisors: Further Improvements.
J Clin Orthod. 2007;41(9):563-573.
11. Rosa M, Zachrisson BU.
The space-closure alternative for missing maxillary lateral incisors: an update.
J Clin Orthod. 2010;44(9):540-549.
12. Rosa M, Zachrisson B.U.
Missing maxillary lateral incisors: new procedures and indications for optimal space closure.
Cap. 25 in "Esthetics and Biomechanics in Orthodontics" - 2nd Edition, 2014; (edited by) R.Nanda.
Elsevier Saunders. 3251 Riverport Lane. St.Louis. Missouri 63043:528-559.
13. Olivadoti A, Doldo T, Treccani M.
Morpho-dimensional analysis of the maxillary central incisor clinical crown in cases of congenitally missing upper lateral incisors.
Progress in Orthodontics. 2009;10:12-19.
14. Yaqoob O, DiBiase A T, Garvey T, Fleming P S.
Relationship between bilateral congenital absence of maxillary lateral incisors and anterior tooth width.
Am J Orthod Dentofac Orthop. 2011;139(3):e229-e233.
15. Mirabella AD, Kokich VG, Rosa M.
Analysis of crown widths in subjects with congenitally missing maxillary lateral incisors.
Eur J Orthod. 2012;34:783-787.
16. Ramazanzadech BA, Ahari F, Hajian S.
Evaluation of tooth size in patients with congenitally-missing teeth.
J Dent Res D Clin D Prospects 2013;7(1):36-41.
17. Wright J, Bosio JA, Chou JC, Jang SS.
Maxillary lateral incisor agenesis and its relationship to overall tooth size.
J Prosthetic Dent 2016;115(2):209-14.
18. Al Rushaid S, Chandhoke T, Utreja A, Tadinada A, Allareddy V, Uribe F.
Three-dimensional evaluation of root dimensions and alveolar ridge width of maxillary lateral incisors in patients with unilateral agenesis.
Progress in Orthodontics 2016;17(1):30.

19. Ludwig B, Zachrisson BU, Rosa M.
Non-compliance space closure in patients with missing maxillary lateral incisors.
J CI Orthod 2013;47(3):180-7.
20. Wilmes B, Bi'Okirch S, Ludwig B, Becker K, Willmann J, Drescher D.
The B-Mesialslider for noncompliance space closure in cases with missing upper laterals.
Semin Orthod 2018;24:66-82.
21. Wilmes B, Ludwig B, Vasudavan S, Nienkemper M, Drescher D.
The T-zone: median vs paramedian insertion of palatal mini-implants.
J Clin Orthod 2016;50:543-51.
22. Lombardo L, D'Ercole A, Latini MC, Siciliani G.
Optimal parameters for final position of teeth in space closure in case of a missing upper lateral incisor.
Progress in Orthodontics 2014;15:63.
23. Drummonda S, Capelli JJr.
Incisor display during speech and smile: Age and gender correlations.
Angle Orthod. 2016;86:631–637.
24. Zachrisson BU and Mjor IA. Remodeling of teeth by grinding. *Am J Orthod Dentofac Orthop* 1975;68(5):545-553.
25. Allgayer S and Barbieri Mezomo M.
Do premolar extractions necessarily result in a flat face? No, when properly indicated.
Dental Press J Orthod 2018 Sep-Oct; 23(5): 82-92.
26. Konstantonis D, Vasileu D, Papageorgiou SN, Eliades T.
Soft tissue changes following extraction vs. nonextraction orthodontic fixed appliance treatment: a systematic review and meta-analysis.
Eur J Oral Sci. 2018 Jun;126(3):167-179.
27. Mendes LM, Janson G, Zingaretti Junqueira-Mendes CH, Garib D.
Long-term profile attractiveness in Class II Division 1 malocclusion patients treated with and without extractions.
Am J Orthod Dentofacial Orthop. 2019 Mar;155(3):362-371.
28. Christou T, Betlej A, Aswad N, Ogdon D, Kau CH.
Clinical effectiveness of orthodontic treatment on smile esthetics: a systematic review.
Clin Cosmet Investig Dent. 2019; 11: e89–e101.
29. Cheng HC, Wang YC.
Effect of nonextraction and extraction orthodontic treatments on smile esthetics for different malocclusions.
Am J Orthod Dentofacial Orthop. 2018;153(1):81-86.
30. De Launy L, Gebeile-Cauty S.
The smile: a challenge in the treatment of class III.
Orthod Fr. 2018;89(1):81-91.
31. Kim E, Gianelly A.
Extraction vs nonextraction: arch widths and smile esthetics.
Angle Orthod 2003;73:354-8.
32. Meyer AH, Woods MG, Mantonc DJ.
Maxillary arch width and buccal corridor changes with orthodontic treatment. Part 2: Attractiveness of the frontal facial smile in extraction and nonextraction outcomes.
Am J Orthod Dentofacial Orthop 2014;145:296-304.
33. Pernet F, Vento C, Pandis N, Kiliaridis S.
Long-term evaluation of lower incisors gingival recessions after orthodontic treatment.
Eur J Orthod. 2019 Mar 29. pii: cjoy086. doi: 10.1093/ejo/cjoy086. [Epub ahead of print].

34. Persson M, Persson EC, Skagius S.
Long-term spontaneous changes following removal of all first premolars in Class I cases with crowding.
Eur J Orthod 1989;11:271-282.
35. Jonsson T and Magnusson TE.
Crowding and spacing in the dental arches: Long-term development in treated and untreated subjects.
Am J Orthod Dentofacial Orthop 2010;138:384-6.
36. Souza RA, Alves GN, Mattos JM, Coqueiro RDS, Pithon MM, Paiva JB.
Perception of attractiveness of missing maxillary lateral incisors replaced by canines.
Dental Press J Orthod. 2018 Sep-Oct; 23(5):65-74.
37. Gomes AF, Pinho T.
Esthetic perception of asymmetric canines treated with space closure in maxillary lateral incisor agenesis.
Int J Esthet Dent. 2019;14(1):30-38.
38. Silveira GS, Valli de Almeida N, Tavares Pereira DM, Trindade Mattos C, Mucha JN.
Prosthetic replacement vs space closure for maxillary lateral incisor agenesis: A systematic review.
Am J Orthod Dentofacial Orthop 2016;150(2):228-37.
39. Schneider U, Moser L, Fornasetti M, Piattella M, Siciliani G.
Esthetic evaluation of implants vs canine substitution in patients with congenitally missing maxillary lateral incisors: are there any new insights?
Am J Orthod Dentofacial Orthop 2016;150(3):416-24.
40. Rosa M, Olimpo A, Fastuca RM, Caprioglio A.
Perceptions of dental professionals and laypeople to altered dental esthetics in cases with congenitally missing maxillary lateral incisors.
Progress in Orthodontics 2013;14:34.
41. Kokich VO Jr, Kiyak HA, Shapiro PA.
Comparing the perception of dentists and lay people to altered dental esthetics.
J Esthet Dent 1999;11:311-324.
42. Kokich VO Jr, Kokich VG, Kiyak HA.
Perceptions of dental professionals and laypersons to altered dental esthetics: Asymmetric and symmetric situations.
Am J Orthod Dentofacial Orthop 2006;130(2):141-51.
43. Pinho S, Ciriaco C, Faber J, Lenza MA.
Impact of dental asymmetries on the perception of smile esthetics.
Am J Orthod Dentofacial Orthop 2007;132(6):748-53.
44. Schalk-Van der Weide Y, Bosman F.
Tooth size in relatives of individuals with oligodontia.
Archives of Oral Biology 1996;41:469-472.
45. Brook A H, Elcock C, Al-Sharood M H, McKeown H F, Khalaf K, Smith R N.
Further studies of a model for the aetiology of anomalies of tooth number and size in humans.
Connective Tissue Research 2002;43:289-295.
46. McKeown H F, Robinson D L, Elcock C, Al-Sharood M, Brook A H.
Tooth dimensions in hypodontia patients, their unaffected relatives and a control group measured by a new image analysis system.
Eur J Orthod 2002;24:131-141.
47. Radia S, Sherif M, McDonald F, Naini FB.
Relationship between maxillary central incisor proportions and facial proportions.
J Prosthet Dent. 2016 Jun;115(6):741-8.
48. Parciak EC, Dahiya AT, AlRumaih HS, Kattadiyil MT, Baba NZ, Goodacre CJ.
Comparison of maxillary anterior tooth width and facial dimensions of 3 ethnicities.
J Prosthet Dent. 2017 Oct;118(4):504-510.

49. Murakamy T, Yokota S and Takahama Y.
Periodontal changes after experimentally induced intrusion of upper incisors in monkeys.
Am J Orthod Dentofacial Orthop 1989 Feb;95(2):115-26.
50. Erkan M, Pikdoken L and Usumezc S.
Gingival response to mandibular incisor intrusion.
Am J Orthod Dentofacial Orthop 2007;132:143.
51. Hochman MN, Chu SJ, and Tarnow DT.
Orthodontic extrusion for implant site development revisited: A new classification determined by anatomy and clinical outcomes.
Semin Orthod 2014;20/3:208-227.
52. Corrente G, Abundo R, Re S, Cardaropoli D, Cardaropoli G.
Orthodontic movement into infrabony defects in patients with advanced periodontal disease: A clinical and radiological study.
J Periodontol 2003;74:1104-1109.
53. Hourfar J, Lucchi P, Ludwig B, Ruff CJ, Rosa M, Kanavakis G.
Esthetic provisional restoration after space closure in patients with missing upper lateral incisors.
J Cl Orthod 2016;50(6):348-57.

Figures and legends

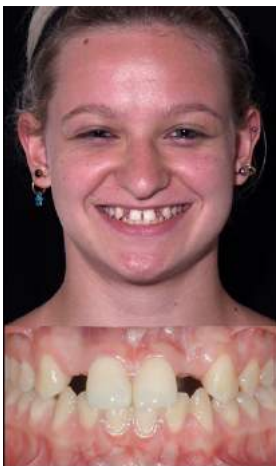

Fig.1: Age 17. Before Space Closure.

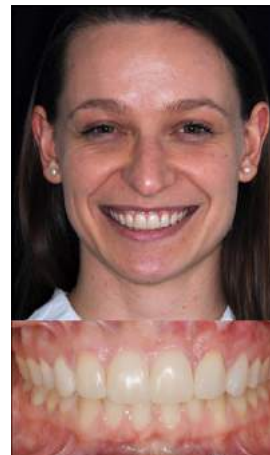


Fig.2: Age 29. 10 years after Space closure and 6 composite restorations made by dr.Patrizia Lucchi

Essayist II
Dr. Renato Cocconi:

Space closure vs space preservation as it relates to craniofacial classification.

Introduction

The incidence of congenitally missing lateral incisors is approximately 2% in a Caucasian population^{1,2}. This form of hypodontia can be bilateral or unilateral; such a condition can occur with a contralateral small or peg shape lateral incisor adding complexity to the restorative options. We should consider that patients with congenitally missing lateral incisors often have narrower teeth than patients without any dental anomalies, except for maxillary first molars³. According to the quadrant analysis, the teeth in the quadrants with missing or peg-shaped lateral incisors are narrower than the teeth in the quadrants with normal lateral incisors. A missing or peg-shaped lateral incisor in the quadrant is a significant factor causing the reduction of the overall mesio-distal tooth widths of that quadrant, the maxillary central incisor being the tooth showing the greatest discrepancy⁴.

Often the Orthodontist is the first to recognize this condition at an early age and he needs to decide how to treat it, interacting with the referring dentist and his/ her restorative team. The interdisciplinary solution should provide proper esthetic outcome, periodontal health and long-term stability.

The space closure solution, especially for bilateral missing laterals, provides satisfactory esthetics and functional long term results⁵⁻⁸ and can be considered a feasible option, attainable already during adolescence. The morphology, size, and shade of the maxillary canine in patients having orthodontic space closure and lateral incisor substitution can have a marked effect on perceived smile attractiveness⁹. These factors have less relevance if the 6 anterior teeth will be restored avoiding an excessive grinding of the canines and restoring them as big laterals together with enlargement of the bicuspid as cuspid and of the central incisors¹⁰. This approach can reduce the risk of long-term space reopening. Since in this form of mild hypodontia a reduction in size is found in both maxillary and mandibular teeth (3), enlargement of mandibular anterior teeth or thickening of maxillary restorations might be necessary to avoid an increased overjet as proposed by Rosa and Zachrisson¹⁰.

The long-term periodontal indexes in space closure appear to be better than the prosthetic solution⁹⁻¹¹ and the esthetic results are judged more favorably by lay people¹².

The space opening solution requires a prosthetic replacement of 2 possible categories: a single tooth implant or a resin-bonded FDP (fixed dental prosthesis)¹³. Single tooth implants have become a very popular prosthetic option, giving the possibility to leave the adjacent teeth untouched¹⁴⁻¹⁶. This solution is often preferred by dentists¹².

After the orthodontic space opening during adolescence, the time of placement of the implants is a major issue to consider. The infraocclusion of the implant-supported restoration¹⁷ is quite common and several individual factors related to facial growth, occlusion, dental continuous eruption and wear should be evaluated. The infraocclusion is not easy to predict and shows great variability.

The indication to place the implant when 2 serial cephalometric cephs, taken 6 months to 1 year apart, do not show any vertical growth (on average 16-17 for girls and 20-21 for men¹⁸⁻¹⁹ seems not to be so effective due to the continuous process of bone remodeling and tooth eruption²⁰⁻²¹. The potential problem of this progressive infraocclusion suggests to delay as much as possible the age of implant placement in the young patient. Therefore, after the orthodontic space opening, a reasonable esthetic and functional solution should be provided from adolescence to adulthood. Furthermore, the frequent problems of darkening of the labial gingiva due to resorption of the alveolar bone^{22,23}, of interproximal papilla health and morphology²⁴, of possible gingival recessions, makes this prosthetic alternative very risky in patients with high smile line and vertical maxillary excess.

The second prosthetic alternative after space opening is a 1-wing resin-bonded FDP²⁶.

Mild hypodontia with smaller teeth (3).

Since "Form is everything except for position and size", the interdisciplinary treatment should address all these 3 factors. The orthodontist should resolve all the positional problems before the restorative dentist will deal at the end of ortho treatment with the form of teeth.

A logic hierarchy of decisions should be followed to create the premises for a stable occlusion, periodontal health and an acceptable dental and facial esthetics. In an interdisciplinary treatment the orthodontist is the first in charge of planning the occlusion considering the problems of dental position and size. Virtual set up can be used to facilitate this task allowing a 3D planning of the occlusion.

Position Before Form

Lower crowding and lower extractions.

The orthodontist should start the occlusal planning from the lower arch: after deciding the proper inclination of the lower incisors, taking into account the crowding and the leveling of the curve of Spee and Wilson. He needs to decide if extractions of lower bicuspids are necessary. This will have an important consequence: the lower bicuspid extraction will call for space closure in the upper arch with bilateral missing laterals.

Upper incisors retraction and class II.

If lower extractions are not necessary, the logical step that follows is to evaluate the orthodontic need for upper incisors retraction. If we intend to correct a positive overjet by orthodontic retraction of the upper incisors, then space closure will be the preferred solution. In this case we should pay attention to

the changes in the nose-lip unit²⁶ and the consequent esthetic limitations, since the upper incisor retraction can induce, as a side effect, a reduction of support for the upper lip and/or excessive projection of the nose.

A large overjet induced by a severe skeletal Class II might require a surgical mandibular or bi-maxillary advancement. In this case, space opening is a viable alternative as long as the space for the laterals is not obtained with an excessive protrusion of the incisors.

Upper crowding.

If the retraction of the upper incisors is not so significant, a third logical step will be to analyze the upper arch size problems with a space analysis of the 2 upper quadrants. In this analysis a space of 6.5 mm is attributed to the lateral incisors, in order to comply with the necessary space for future implants²⁴, or to avoid an excessive grinding of cuspids in case of laterals substitution. This implies a space of at least 9 mm for the small central incisors for better high-width ratio. In this perspective, if we have a severe lack of space (4 mm or more in each quadrant), space closure will be the most reliable option. Class II molar relationship will be achieved by mesialization of posterior buccal upper segments. This orthodontic movement can be facilitated by the use of TADs, to reduce biomechanical side effects.

The significant potential crowding makes the space opening option less reliable and it can end up with an excessive protrusion of the incisors or an insufficient space for restorations.

Molar distalization.

If the lack of space is less relevant (less than 3mm) the distalization of the upper buccal segments and of the upper cuspids should provide the requested 6.5 mm for the upper lateral prosthetic replacement. Distalization of maxillary molars can be significantly improved by the use of TADs²⁷⁻³⁰ but it become less predictable when we deal with a mandibular deficit, especially if the molars are in full Class II and the adolescent patient shows a vertical or a posterior mandibular growth pattern. If mandibular growth is not favorable, distalization of the buccal segments in achieving a Class I occlusion and proper spaces for the lateral incisors becomes less predictable.

Unilateral missing lateral.

A common challenging situation is when we have a missing lateral in one quadrant and a small lateral in the other. Following the previously mentioned logical steps, if we need lower bicuspid extractions or if we need to retract upper incisors to attain a positive overjet, the extraction of the small lateral and a symmetrical space closure should be considered, thus creating the premises for symmetric restorations.

We can have patients with a missing lateral and a Class II on one side and a small lateral and a Class I on the opposite side (subdivision). The space opening solution may allow to prosthetically replace the missing lateral and restore the small lateral giving both of them a normal size and achieving a Class I occlusion. Before we follow this solution, it is advisable to check the presence of a dental asymmetry in the lower arch (often related to a mild skeletal asymmetry). In fact, distalization can be more demanding on the side where the lower cuspid is more retrusive (shorter mandibular size). In this case it might be preferable to extract the small lateral and proceed with symmetrical space closure or to face the restorative challenge of the cuspid substitution on one side and the enlargement of the small lateral on the opposite side. In both cases, restorations of all the anterior teeth are often needed.

Class III.

In an adolescent with a mild skeletal Class III we can choose the opening or closing option, depending upon the amount of the available space. The use of TADs makes the required orthodontic movements more predictable. Attention should be paid to avoid excessive Class III dental compensation of the incisors, for esthetic reasons and not to preclude the surgical option in case of unfavorable late growth. Retraction of the upper incisors and consequent space closure, using spaces provided by the missing lateral can be performed in some cases of surgical class III³¹.

Spaced upper arch and size of teeth.

Space opening is the first option to consider in cases of a spaced upper arch with a Class I molar relation. It can be challenging to distalise upper cuspids when they have erupted in a mesial position. TADs and corticotomies can facilitate this orthodontic movement³²⁻³³. The orthodontic distalization of the cuspids increases the buccolingual alveolar width³⁴ that will remain stable over time³⁵. In our experience this event will not reduce the necessity to improve hard and soft tissue support for future implants or ovate pontics.

Upper and lower teeth can be both small in size, therefore it is possible to orthodontically obtain a Class I occlusion, but with small spaces for the laterals (around 5 mm). Posterior stripping can be used to obtain at least 6 mm of space for future implants but this size can be excessive if the upper centrals are also small (intra arch size discrepancy).

If implants will be used, it is still advisable to orthodontically open a space both intra-coronal and intra-radicular of 6.5 mm^{24,34} for upper laterals. If this is the prosthetic choice and the centrals are only 7 mm in width, the orthodontist should open an extra space of at least 7.5-8 mm to accommodate for their enlargement. The advent of smaller implant and platform switch design⁴² has been shown to have a positive effect on the amount of bone remodeling, more favorable than the one attained with standard implants³⁰. If the choice is to maintain the smaller size of teeth, bonded FDPs³⁶ can be an alternative to implants.

Smile line - vertical maxillary deficit and excess.

We should also consider the smile line and the vertical position of the maxilla. A low smile line and a vertical maxillary deficit favor implants as a convenient prosthetic solution.

Vertical maxillary excess and hyperdivergent growth pattern of the mandible (i.e. long faces) often present a high smile line and lip incompetence. From an esthetic standpoint, when both options are available, the space closure presents long term advantages over the space opening. A high smile line is not per se a contra indication for space opening, but it is wise to consider a safer prosthetic choice that can reduce the long-term risks related to implants placed in the esthetic zone.

A resin bonded FDP can be an option. 1-wing FDP can overcome some of the instability issues found with a 2-wing design³⁶, where deep overbite and proclined incisors seem to be related to a higher incidence of failure³⁶; directional mobility problems are reduced with a 1-wing design^{37,38} with a better long-term prognosis³⁹.

The material of choice, the bonding surface, the bonding technique, the thickness of the connector are parameters relevant to the long-term prognosis of the 1-wing design⁴⁰. The orthodontist can bond a 0.5 mm thickness of resin on the palatal surface of the central incisors or cuspids during the orthodontic leveling to reduce the enamel preparation for the FDP. All contacts in excursions must be carefully checked and carefully examined, regarding the cantilever⁴¹ and the alveolar ridge. Often a soft tissue augmentation is necessary to optimize the emergence profile of the ovate pontic. Long term, an ovate pontic can be affected by the ongoing eruption of the adjacent teeth, but the esthetic consequences are less relevant than a significant infraocclusion of an implant in the esthetic zone.

Form after position

Orthodontic finishing.

During the finishing stage of treatment, in case of symmetric or asymmetric space opening or closure, the orthodontist should follow the indications of the restorative dentist to obtain a tooth position that will allow the best restorative outcome with minimally invasive preparation or no preparation. The restorative dentist knows better to what extent he can compensate for minimal positional inefficiencies or orthodontic limitations. Digital smile design could help the visualization and the communication among the team members.

Post orthodontic retention during adolescence.

After orthodontic treatment, the adolescent patients with missing laterals need a restorative solution that is esthetically satisfactory in this very important period of life. After appliance removal, teeth need to be retained by thermoplastic aligners or by fixed composite retainers, to avoid minimal dental movements before restoration.

Composite restorations (direct or indirect) or ultra-thin CAD/CAM (PICN or RNC) veneers⁴³ can offer proper esthetic and functional results. At a later age ceramic veneers can be considered. Altered passive eruption can represent an esthetic limitation and might require a minimal invasive periodontal surgery.

In case of space opening the actual propensity is to delay as much as possible the implant placement in the esthetic zone. Therefore, after ortho treatment, we should apply prosthetic solutions that need to endure several years, offering a feasible esthetic and functional result during late adolescence and young adulthood. The use of a removable retainer with a prosthetic tooth is an easy and inexpensive

option, but it cannot be considered an acceptable long-term retainer. A night time Hawley retainer can be considered, or a night guard can be prescribed if the patient shows bruxing habits.

A 1-wing resin bonded FDP could be an excellent temporary solution both for esthetics and function; it might also become a permanent solution if the patient is satisfied and might not be willing to proceed with implants in the future. In case of breakage or debonding it can be easily repaired. If an improvement of the pontic-site is required, in our experience often parents resist the option of a soft tissue enhancement to obtain an esthetic ovate pontic.

It has been proposed to use a mini implant retained pontic as a semi-permanent solution, that allows the vertical growth of the alveolar process and improve its bone density over a period of 5 years⁴⁴. Still the convergence of the roots during the retention phase²⁵ might be a problem for the implant placement in the future.

Conclusions

1. Today the adolescent patient often requires a satisfactory esthetic solution after orthodontic treatment.
2. Congenitally missing laterals often require interdisciplinary treatment by an experienced team.
3. Clinical experience and technical skills of the team are relevant to the success of the overall treatment.
4. Dental position should be planned before dental form.
5. Digital planning and TADs can help the treatment.
6. The option of space opening or closing is not simply based on the personal preference of the operator and must involve an informed patient in the final decision.
7. Some positional situations (lower and upper lack of space, upper incisors retraction) can preclude the option of space opening.
8. Some growth patterns (Class II with vertical or posterior mandibular growth) can reduce the options of space opening.
9. Some skeletal conditions (vertical maxillary excess) or morphologic conditions (high smile-line) create esthetic limitations to the options of space opening.
10. In case of space opening the small size of teeth should be considered and might contrast with an ideal 6.5 mm space for an implant.
11. In case of space opening 1-wing FDPs can offer a long-term esthetic solution.
12. 1-wing FDPs can represent a viable alternative to implant restorations, whose survival rate differs from the success rate.
13. In case of space closure, the 6 anterior teeth are often involved in the restorative treatment.
14. Composite restorations can represent a valid restorative option.
15. Will no prep or minimal prep CAD/CAM veneers be an alternative considering the restorative skills of an average dentist?
16. Is minimal invasive surgery acceptable to address situations of passive eruption to improve the esthetic outcome?
17. Soft tissue augmentation could be useful for the esthetics of the ovate pontic but difficult to be accepted in the adolescent patient.

References

4. Brook A H.
Variables and criteria in prevalence studies of dental anomalies of number, form and size.
Community Dent Oral Epidemiol 1975; 3: 288–293.
2. Polder, B.J.
A meta-analysis of the prevalence of dental agenesis of permanent teeth.
Community Dent Oral Epidemiol. 2004;32:217–226
3. Mirabella AD, Kokich VG, Rosa M.
Analysis of crown widths in subjects with congenitally missing maxillary lateral incisors.
Eur J Orthod 2012;34:783-7.
4. Bozkaya E, Canigur Bavbek N, Ulasan B.
New perspective for evaluation of tooth widths in patients with missing or peg-shaped maxillary lateral incisors: Quadrant analysis
Am J Orthod Dentofacial Orthop 2018;154:820-8
5. Tuverson DL.
Orthodontic treatment using canines in place of missing maxillary lateral incisors.
Am J Orthod 1970;58: 109-27.

6. Thordarson A, Zachrisson BU, Mjor IA.
Remodeling of canines to the shape of lateral incisors by grinding: a long-term clinical and radiographic evaluation.
Am J Orthod 1991;100:123-32.
7. Robertsson S, Mohlin B.
The congenitally missing upper lateral incisor. A retrospective study of orthodontic space closure versus restorative treatment.
Eur J Orthod 2000;22:697-710.
8. Zachrisson B, Rosa M, Toreskog S.
Congenitally missing maxillary lateral incisors: canine substitution.
Am J Orthod Dentofacial Orthop 2011;139:435-44.
9. Brough E, Donaldson AN, Nain FB.
Canine substitution for missing maxillary lateral incisors: the influence of canine morphology, size, and shade on perceptions of smile attractiveness.
Am J Orthod Dentofacial Orthop 2010;138:705.e1-e9
10. Rosa M, Zachrisson BU.
Integrating space closure and esthetic dentistry in patients with missing maxillary lateral incisors.
J Clin Orthod 2007;41:563-73.
11. Rosa M, Lucchi P, Ferrari S, Zachrisson BU, Caprioglio A.
Congenitally missing maxillary lateral incisors: Long-term periodontal and functional evaluation after orthodontic space closure with first premolar intrusion and canine extrusion
Am J Orthod Dentofacial Orthop 2016;149:339-48.
12. Schneider U, Moser L, Fornasetti M, Piattella M, Siciliani G.
Esthetic evaluation of implants vs canine substitution in patients with congenitally missing maxillary lateral incisors: Are there any new insights?
Am J Orthod Dentofacial Orthop 2016; 150: 416–424.
13. Kokich VO Jr, Kinzer G A, Janakiewski J.
Congenitally missing maxillary lateral incisors: restorative replacement.
Am J Orthod Dentofacial Orthop 2011; 139: 435, 437, 439.
14. Romeo E, Chiapasco M, Ghisolfi M, Vogel G.
Long-term clinical effectiveness of oral implants in the treatment of partial edentulism. Seven-year life table analysis of a prospective study with ITI dental implants system used for single-tooth restorations.
Clin Oral Implants Res 2002;13:133-43.
15. Covani U, Crespi R, Cornellini R, Barone A.
Immediate implants supporting single crown restoration: a 4 year prospective study.
J Periodontol 2004;75:982-8.
16. Garber DA, Salama MA, Salama H.
Immediate total tooth replacement.
Compend Contin Educ Dent 2001;22:210-8.
17. Thilander B, Odman J, Lekholm U.
Orthodontic aspects of the use of oral implants in adolescents: a 10-year follow-up study.
Eur J Orthod 2001;23:715-31.
18. Kokich VG.
Managing orthodontic-restorative treatment for the adolescent patient.
In: McNamara JA, Brudon WI, editors. *Orthodontics and dentofacial orthopedics*.
Ann Arbor, Mich: Needham Press; 2001. p. 423-52.
19. Fudalej P, Kokich VG, Leroux B.
Determining the cessation of vertical growth of the craniofacial structures to facilitate placement of single-tooth implants.
Am J Orthod Dentofacial Orthop 2007;131 (Suppl): p. 59-67.
20. Iseri H, Solow B.
Continued eruption of maxillary incisors and first molars in girls from 9 to 25 years, studied by the implant method.
Eur J Orthod 1996;18:245-56.
21. Chang M, Wennstrom JL, Odman P, Andersson B.
Implant supported single-tooth replacements compared to contralateral natural teeth. Crown and soft tissue dimensions.
Clin Oral Implants Res 1999;10:185-94.
22. Dueled E, Goffredsen K, Damsgaard MT, Hede B.
Professional and patient-based evaluation of oral rehabilitation in patients with tooth agenesis.
Clin Oral Implants Res 2009;20:729-36.
23. Sabri R.
Management of missing maxillary lateral incisors.

- J Am Dent Assoc 1999;130:80-4.
24. Tarnow DP, Cho SC, Wallace SS.
The effect of inter-implant distance on the height of the inter-implant bone crest.
J Periodontol. 2000 Apr;71(4):546-9.
25. Olsen TM, Kokich VG Jr.
Postorthodontic root approximation after opening space for maxillary lateral incisor implants.
Am J Orthod Dentofacial Orthop 2010;137:158-9.
26. Cocconi R, Raffaini M, Amat P.
From orthodontics to Ortho Facial surgery.
Orthod Fr. 2016 Sep;87:247-271.
27. Antonarakis GS, Kiliaridis S.
Maxillary molar distalization with noncompliance intramaxillary appliances in Class II malocclusion. A systematic review.
Angle Orthod 2008;78:1133-40.
28. Cornelis MA, DeClerck HJ.
Maxillary molar distalization with mini plates assessed on digital models: a prospective clinical trial.
Am J Orthod Dentofacial Orthop 2007;132:373-7.
29. Sugawara J, Kanzaki R, Takahashi I, Nagasaka H, Nanda R.
Distal movement of maxillary molars in nongrowing patients with the skeletal anchorage system.
Am J Orthod Dentofacial Orthop 2006;129:723-33.
30. Fudalej P, Antoszewska J.
Are orthodontic distalizers reinforced with the temporary skeletal anchorage devices effective?
Am J Orthod Dentofacial Orthop 2011;139:722-9.
31. Cozzani M, Lombardo L, Gracco A.
Class III malocclusion with missing maxillary lateral incisors
Am J Orthod Dentofacial Orthop 2011;139:388-96.
32. Aboul-Ela SM, El-Beialy AR, El-Sayed KM, Selim EM, El-Mangoury NH, Mostafa YA.
Miniscrew implant-supported maxillary canine retraction with and without corticotomy-facilitated orthodontics.
Am J Orthod Dentofacial Orthop 2011;139:252-9.
33. Long H, Pyakurel U, Wang Y, Liao L, Zhou Y, Lai W.
Interventions for accelerating orthodontic tooth movement: a systematic review.
Angle Orthod 2013;83:164-71.
34. Kokich VG.
Managing orthodontic-restorative treatment for the adolescent patient.
In: McNamara JA, Brudon WI, editors. Orthodontics and dentofacial orthopedics.
Ann Arbor, Mich: Needham Press; 2001. p. 423-52.
35. Novackova S, Marek I, Kaminek M.
Orthodontic tooth movement: bone formation and its stability in time.
Am J Orthod Dentofacial Orthop 2011;139:37-43.
36. Creugers NH, Kayser AF, Van't Hof MA.
A seven-and-a-half-year survival study of resin-bonded bridges.
J Dent Res 1992;71:1822-5.
37. Kern M.
Clinical long-term survival of two-retainer and single-retainer all-ceramic resin bonded fixed partial dentures.
Quintessence Int 2005;36:141-7.
38. Kern M, Sasse M. Ten-year survival of anterior all-ceramic resin-bonded fixed dental prostheses J Adhes Dent. 2011;13(5):407-10.
39. Wei YR, Wang XD, Zhang Q, Li XX, Blatz MB, Jian YT, Zhao K
Clinical performance of anterior resin-bonded fixed dental prostheses with different framework designs: A systematic review and meta-analysis.
J Dent. 2016 Apr;47:1-7.
40. Blatz MB, Alvarez M, Sawyer K, Brindis M.
How to Bond Zirconia: The APC Concept
Compend. Contin Educ. Dent. 2016; 37(9):611-617
41. Decock V, De Nayer K, De Boever JA, Dent M.
18-year longitudinal study of cantilevered fixed restorations.
Int J Prosthodont 1996;9:331-40.

42. Lazzara RJ, Porter SS.
Platform switching: a new concept in implant dentistry for controlling postrestorative crestal bone levels.
Int J Periodontics Restorative Dent 2006;26:9-17.

43. Patroni S., Cocconi R.
From orthodontic treatment plan to no prep CAD/CAM temporary veneers.
Int. J. Esth. Dentistry Vol 12. N 4. Winter 2017.

44. Roberto Ciarlantini and Birte Melsen, Semipermanent replacement of missing maxillary lateral incisors by mini-implant retained pontics: A follow-up study Am J Orthod Dentofacial Orthop 2017;151:989-94.

Discussion Session I (90 min)

The recorded discussion aims to be published. It should be organized in a constructive way by the Moderator. The discussion ideally will reach an outcome of consensus conclusions.

Session II

Replacing the missing tooth and growth.

Moderator: Dr. Antoun Hadi

Session's Introduction

For more than 50 years, dentistry has sought a more conservative approach to replacing a single missing tooth versus a conventional fixed prosthesis, which involves the cutting of sound tooth structure. Treatment possibilities have evolved from bonding a natural extracted tooth or a composite resin restoration to the adjacent teeth, to the adhesive bridge and lately to the single-implant-supported crown.

Advances in conservative dentistry have been made and different treatment modalities are proposed including the edentulous space closure and substitution of missing teeth, gap opening and tooth replacement with adhesive bridges and gap distribution or shifting and restorative compensation. All these treatment options have shown good long-term survival rates and esthetic results but there remains a potential for relapse, debonding and fractures¹. On the other hand, the single-implant-supported crown is a predictable method for tooth replacement. It allows a conventional oral hygiene technique, while stability and function are improved. Also, soft tissue modifications can be achieved, including recreation of the interproximal papillae. When placing an implant in the esthetic area, in most cases augmenting hard and soft tissues is also required. While osseointegration around implants is a well-documented phenomenon, the implant designs continue to undergo structural modifications in order to fulfill the prosthetic requirements, aiming to meet the challenge of achieving esthetic results.

One of the most prevalent cause of anterior tooth loss is childhood trauma or to congenital disorders. Timing of implant placement for those young patients is paramount. Placement of implants at an early age when the face is still growing towards different directions - transverse, sagittal, and vertical - could result in implant infra occlusion, buccal/lingual disharmony, diastema, gradual loss of labial bone, lingual shifting and an altered gingival profile^{2,3}. Moreover, for the growing child, early implant ankylosis poses an even greater risk, because it may disturb normal development of the jawbones. In the same manner, adult patients who are dentally mature, are also not immune to altered hard and soft-tissue levels as reported by several authors, due to the continuous tooth eruption of the neighboring teeth.

Historically with the advent of implantology, restorative dentistry techniques in treating partial or full edentulism, have been essentially considered as a therapeutic option only for temporization. Except that, as esthetic failure cases of osseointegrated implants have been observed when implant supported restorations have been applied for the replacement of anterior missing teeth, restorative dentistry is gaining more interest, particularly through the evolution of bonding techniques and the relevant biomaterials.

Finally, should we consider that neither of the two field is superior to the other and that both are reliable techniques? Or does patient selection prevail, given the fact that every patient is unique? The purpose of this session is to unlock the mystery and to know how to set the indication of these therapeutic options through clinical cases discussion and based on expert opinion and on literature data.

References:

1. Priest G.

The treatment dilemma of missing maxillary lateral incisors-Part I: Canine substitution and resin-bonded fixed dental prostheses. *J Esthet Restor Dent.* 2019;29:1-8

2. Cocchetto R, Pradies G, Celletti R, 2. Cocchetto R, Pradies G, Celletti R, Canullo LL.

Craniofacial growth in adult patients treated with dental implants in the anterior maxilla. *Clin Implant Dent Relat Res.* 2019 Apr 29.

3. Heij DG, Opdebeeck H, van Steenberghe D, Kokich VG, Belser U, Quirynen M.

Facial development, continuous tooth eruption, and mesial drift as compromising factors for implant placement. *Int J Oral Maxillofac Implants.* 2006;21:867-78.

Essayist III

Dr. Konrad Meyenberg

Adhesive restorative options:

Restorative space management in the anterior zone with or without orthodontic pretreatment - some clinical considerations and case presentations

Some general considerations

An unfavorable relationship between the form and dimension of the dental arch and the number, dimension and shape of the existing teeth (typical Bolton 3- or 6-discrepancy¹, malformed or undersized teeth, agenesis of teeth, tooth loss due to early trauma) can pose several aesthetic, biologic and functional problems. In many cases, an optimal result cannot be achieved with orthodontic, restorative or reconstructive means alone. Furthermore, patient desires, capacity of compliance and financial conditions are important factors to be included in the treatment concept²⁻⁶.

For all options discussed below the clinical sustainability is well documented in the literature. They all show high survival rates and low complication rates in the hands of the experienced clinician.

From the multitude of long-term studies, systematic reviews and case documentations, it can be extrapolated that both **resin bonded bridges**⁷⁻¹⁸ and **veneers**¹⁹⁻²⁵ behave similarly well and may reach **10 years survival rates** of 95% or more and reintervention rates over 10 years lower than 5%-10%, given proper indication and handling^{10,11,22,26}.

The cost-effectiveness of resin-bonded bridges extrapolated over the lifetime of a patient is also very favorable compared to full-crown bridges and single tooth implants¹⁸. Since currently the standard extension of a resin-bonded bridge is 2-unit (1 wing) and not 3-unit (2 wings) anymore, the risk of secondary caries because of loose wings is no longer relevant¹⁷. The standard materials for resin-bonded bridges are either zirconia or lithium- disilicate-glass-ceramics^{11,13-16}.

Glass ceramic veneers seem to perform slightly better than feldspathic veneers, indicating that materials with increased strength show better clinical performance²⁵. There are also attempts from the industry to use even stronger materials like **Zirconia** to fabricate veneers as well. However, since there neither are long-term results nor sufficient clinical experience available it should be considered today as an experimental procedure.

Direct restorations with composites are today an indispensable attractive non-invasive way of reshaping teeth. The essential techniques for success are widely available and very well documented²⁶⁻³⁰. The multitude of parameters such as type of adhesive materials and procedures, handling properties, curing techniques, operator skills et cetera have an explicit important influence on the outcome. In line with this, a recent systematic literature review shows quite inhomogeneous results. Some data however reach the same level as veneers³¹. In the light of easier modes of reintervention, and given a proper indication, direct composites cannot be regarded as principally inferior to veneers anymore.

The **goals of modern treatment concepts** must include high longterm success, minimal invasiveness and high potential for reintervention with minimal risk of complications as *medical-ethical foundation*²³. This is the case with the aforementioned options. This essay will concentrate on the available restorative and reconstructive adhesive options, but will not discuss the detailed implantologic or orthodontic options, which are presented in separate essays.

Restorative or reconstructive corrections without preceding orthodontic treatment?

If the goals of the patient cannot be achieved with orthodontics alone, the question remains whether they could be achieved with restorative and reconstructive measures alone as a significant simplification of the whole process. The premise for this however is that the occlusion is rated as stable on the long run. As long as this is possible in a minimally invasive and reintervention-friendly way, restorative or reconstructive treatment alone is an attractive option for the patient to minimize the risks of arch instability, tooth position instability and relapse after orthodontic treatment, in addition to the unavoidable lifetime dentoalveolar and jaw basis changes.

From a periodontal and preventive standpoint, this is acceptable as long as the roots are in a favorable position, and the tooth crowns must not be prosthetically retruded but would be protruded and enlarged. A favorable root position means that the emergence at the gingival level is correct and in line with the adjacent teeth. A clear no-go for prosthetic compensation alone is a situation with heavily crowded teeth. Above all if teeth are conoid or slightly lingually inclined, the minimal-invasive adhesive options are inviting.

Orthodontic treatment alone to completely avoid restorative or reconstructive corrections?

It looks tempting at first glance to avoid any restorative or reconstructive corrections and close gaps irrespective of missing or undersized teeth. If the functional and aesthetic analysis of the existing teeth allows it, this is the preferable option. There is no evidence that space closure compared to space opening in the case of missing upper lateral front teeth would lead to an increased rate of TMJ-problems, recessions, abfractions and abrasions³³⁻³⁶. However, this may in some cases lead to aesthetically less satisfactory results⁶.

In the light of the aging dentition, it must also be taken into account that a simple orthodontic concept of just closing gaps without respect to proper dimensions and proportions of the respective teeth in regard to adequate arch and face dimensions can lead to practically unsolvable aesthetic problems later on, when patients want to improve the aesthetics of the aging dentition, but the size, position and playground for shape improvements is limited by a strongly limited space available due to initially to small teeth.

Restorative and reconstructive options

The 5 restorative and reconstructive options to treat a dentition with anterior gaps may be summarized as follows, as single measures or in combination, and with or without a preceding orthodontic treatment phase.

1. **Gap closure** and substitution of missing teeth: restorative transformation of substituted teeth into homologous teeth with odontoplasty, direct composite, etched pieces or porcelain veneers.
2. **Gap opening** and tooth replacement with all-ceramic adhesive bridges, including pontic site development.
3. **Gap distribution** and restorative compensation with direct composite restorations, etched pieces or porcelain veneers.
4. **Gap shifting** and restorative compensation with all-ceramic adhesive bridges, composite, etched pieces or veneers.
5. **Gap compensation** by reconstructive compensation without orthodontics.

As **reconstructive tools** to be used for the aforementioned options, the following means must be considered:

A) Adhesive form corrections:

Composite restorations³¹ or ceramic veneers³⁴ offer excellent long-term results. Whereas composites will preferably be used in the growing patient or to recontour parts of the clinical crown, veneers will be preferred if the clinical crown as a whole, need a change in shape and dimension, e.g. in a case of a substitution of a central by a lateral incisor, or a color shift is needed which cannot be achieved by external bleaching only (e.g. in a case of a substitution of a lateral incisor by a cuspid)²¹.

B) Adhesive tooth replacement:

If one tooth is missing, the concept of **2-unit adhesive bridges** is widely accepted as the most promising solution¹¹, if all-ceramic bridges may be used. Either zirconia¹³⁻¹⁵ or glass-ceramic¹⁶ frameworks perform well. If a 3-unit resin bonded bridge is planned to keep the position of the adjacent teeth or to improve the load capacity, a classical metal framework with retentive micro-preparations⁷⁻¹⁰ should be considered, since all-ceramic frameworks for this indication do not show a promising longterm outcome¹¹. Also, if more than one tooth needs to be replaced, metal frameworks are still preferred. As framework materials, either non-precious or noble alloys can be used^{7,9-11,17}.

Case presentation and some technical considerations

10 illustrative cases are shown in short to illuminate the considerations and give some evidence from the literature concerning important technical details.

It is evident that as a clinician we need to find answers to the clinical challenges and the related questions, accepting that we will not find satisfying answers to all the questions when we plan a case. The main consideration therefore is to use a progressive approach. This means the younger the patient the more important is the potential for reintervention, and subsequently the more important are minimally invasive concepts.

For the growing and young adult patient, direct techniques are therefore first choice, whereas for mature patients, degradation and fatigue of tooth substance may be better compensated by slightly more invasive indirect techniques such as full veneers or even bonded partial all-ceramic crowns, when in addition bleaching is not any more effective to compensate darkened tooth colors.

Gap closure

restorative transformation of substituted teeth into homologous teeth with direct composite or veneers.

Case 1: Both upper cuspids were placed orthodontically at the position of the missing lateral incisors (agenesis). Since the cuspids were rather small and not differing much from the color of the central incisors after external bleaching, which is a good indication for this approach, only incisal shortening and a minimal shape correction with direct composite are necessary in such a case. The correct orthodontic positioning of the cuspid hereby is essential: adequate extrusion to achieve an ideal gingival architecture⁶.

Case 2: The cuspids at the position of the missing laterals were considerably darker than the other front teeth and not well responding to an external bleaching. Therefore, two thin veneers (feldspar porcelain) with minimal preparation were inserted to compensate both shape and color of the cuspids. The missing permanent lower central incisors were replaced with a 4-unit adhesive bridge (pfm-technique).

Case 3: The two upper centrals were lost due to an accident as a young girl. The gap was closed by moving the remaining front teeth towards the midline. Since it was a class II occlusion with prospective missing space in the buccal area, this was an elegant solution. If all teeth had been present, two premolars would have had to be extracted in the upper jaw. The two laterals in the position of the centrals first were built up with composite, and in a later phase at around 20 years of age rebuilt as centrals with all-ceramic partial crowns.

Gap opening

tooth replacement with **all-ceramic adhesive bridges**, including pontic site development.

The following rules for construction should be followed:

Recommended minimal dimensions of the framework in the anterior zone

- A) **connector:** height x width **3x2 mm for Zirconia, 4x4mm for Lithium- Disilicate** glass-ceramics¹¹.
- B) **gap width:** > 7mm should be considered as an **increased risk for fracture** for a 2-unit all-ceramic bridge¹¹.
- C) **wing dimensions: bonding area for the wings** should reach **30mm²** (preferably in enamel only) to properly withstand shear forces under loading, and the recommended **thickness** should ideally be **0.7mm or greater**, both for all-ceramic or metallic frameworks¹¹.

Case 4: Both upper lateral incisors were missing (agenesis) and elsewhere replaced with bonded 3-unit ZrO₂-bridges. These bridges broke and debonded after a short time, as was to be expected. This is a typical example of what can go wrong if basic rules are violated. It is obvious from the literature that all-ceramic adhesive bridges should principally be constructed as 2-unit bridges^{20,22}. In addition neither the wing extension nor the wing thickness were respected. The defects resulting from the inadequate former preparation of the cuspids and inadequate wing area were rebuilt with composite, and the residual defects at the central incisors used as positional grooves for the new frameworks. A shallow palatal groove and rounding off of the palatal enamel ridges at the connector site is helpful to allow proper seating and better stability of the framework. In addition, overcontouring of the margins can be avoided. Due to the limited space for the adhesive wings, a 3Y partially stabilized ZrO₂ framework was used. The use of glass-ceramics is not advisable in this case. A thin ceramic veneering is performed on the buccal side of the pontic.

What type of zirconia should be used for adhesive bridges?

3Y partially stabilized ZrO₂ is the material of choice. Generally, the use of 4Y- or 5Y-ZrO₂ is not recommended. The increased content of cubic (fully stabilized) ZrO₂ leads to considerably lower mechanical properties³⁷⁻⁴¹. These materials may have a slightly better transparency as one of the aesthetic components compared to 3Y-ZrO₂, however the respective refractive index around 2 or more still is much higher than enamel, dentin, cementum and lithium-disilicate glass-ceramic materials (all around 1.5 - 1.6)^{40-43,50}, which causes still more diffuse internal and surface reflection⁴⁴. The aesthetic appearance of different Zirconias is in a complex way related to the different microstructures and compositions. New developments of 3Y- ZrO₂ with nano grain size particles may address the combination of optimal mechanical and optical properties in a more promising way⁴⁴.

Adhesive cementation of Zirconia frameworks

The frameworks are sandblasted using a **tribochemical conditioning** of the surface with 30 µm particle size SiO₂/Al₂O₃ (Rocatec Plus, 3M Espe, Seefeld, Germany) and a pressure of 2.5 bar (distance 10mm, perpendicular blasting direction) to achieve an active and ideally textured surface. The ceramic surface is then first cleaned in an ultrasonic device (alcohol), and primed with a combination of MDP & Silane (Ceramic Primer Plus, Kuraray, Japan)⁴⁵⁻⁵⁰. As cement, the transparent Panavia V5 (Kuraray, Japan) is used after acid etching the enamel and conditioning and priming dentin & enamel with the tooth conditioner of Panavia V5. This approach is the most predictable and easiest to use in the clinic¹¹. An important remark must be made here: Panavia V5 in contrast to Panavia 21 does not contain MDP in the pastes itself, therefore the use of the MDP- (and Silane-) containing primer on the Zirconia surface is imperative.

Development of the pontic-site area

If we have to deal with a unilaterally missing lateral incisor (agenesis), often the contralateral incisor is smaller than normal or has a conoid shape. This is an ideal indication for an adhesive bridge to replace the missing tooth, since the smaller the gap the better the mechanical situation for a 2-unit bridge. In addition, the edentulous ridge area is easier to condition for the pontic integration or for soft tissue augmentation procedures⁵¹⁻⁵³. As standard pontic design, an ovate pontic design should always be preferred due to its aesthetic advantages, its biologic acceptance and ease of cleaning with dental floss^{52,54}.

In Case 5, the unilateral missing lateral incisor were replaced with a 2-unit all- ceramic adhesive bridge after orthodontic treatment. Since the tooth color was rather transparent and light at the same time, and the intermaxillary space sufficient for a 4x4mm connector design, a glass-ceramic material (Lithium Disilicate, Ivoclar, Schaan, Lichtenstein) could be used, with thin buccal veneering of the pontic¹⁶. As a preparation concept, an almost non- prep design may be used. The enamel is just rounded at the connector site, but no other preparation is required. The downside of a non-prep and non- retentive design is the difficulty of proper positioning the wing during cementation. The ceramic is etched for 20 sec with HF according to the manufacturer's instructions for use (Ivoclar, Schaan, Lichtenstein), a primer containing silane is used and the enamel etched with phosphoric acid^{50,55,56}. As cement, a flowable light-cured composite of medium viscosity is used.

The pontic-site can be developed with different methods^{4,51,52}.

If it is a narrow gap between the adjacent teeth before the orthodontic opening, ridge augmentation procedures often can be avoided, when the teeth are slowly separated from each other. A provisional removable denture can be used after completion of the orthodontic treatment to displace and redistribute the soft tissue and to form the papillae. If this is not sufficient, a tissue augmentation procedure is indicated, mostly soft tissue only^{51,53}. The advantage of a pontic mainly is that there is no need for a bony socket as requested for an implant. The site must then be developed to accept an ovate pontic, by using the provisional removable partial denture as a scaffold. Underlining the provisional pontic with composite to shape the soft tissue non-surgically into the right form is very effective.

However, the edentulous ridge will neither increase its vertical dimension during the growth period, nor will it later adapt to the repositioned adjacent teeth during the lifelong eruption. Only the passive eruption of the adjacent teeth will compensate partially in this respect the continuing active eruption, if an ovate pontic with a deep basal part was integrated initially. Often it can be observed over time that the pontic loses its initial tight soft tissue contact due to the effects described above. However, this is mostly much better tolerated by the patients than an implant that seems to be in an intruded and protruded position due to the same longterm effects. The following case may illustrate this process.

Case 6 shows a situation with a missing central incisor after an accident early on in the life of this patient. The ridge was rebuilt using both a xenograft material (BioOss, Geistlich, Switzerland) and a soft tissue graft to build up the ridge. An adhesive 3-unit PFM-bridge was inserted almost 30 years ago. After 22 years the bridge still is in place, but we now see the decreased contact between pontic and soft tissue receptor site. From a mechanical standpoint, 3- or 4-unit adhesive bridges should preferably be supported by a **metallic framework**^{21,22}, either non-precious alloys, or noble alloys, which are aesthetically easier to veneer with porcelain. The **bonding procedure**⁵⁷⁻⁶⁰ is principally the same as already described above for ZrO₂-frameworks. However, to prevent a grayish effect of the wings on the abutment teeth, an opaque cement must be used (e.g. Panavia V5 OP, Kuraray, Japan).

4-unit adhesive bridges with a metal framework to replace two missing lower centrals may also be able to stabilize the arch after orthodontics without the need for a wire retainer (Case 2), in contrast to two separate 2-unit all-ceramic bridges, where in most instances a wire retainer should be used together with the bridges.

In Case 7 both upper central incisors were lost early in the life of this patient. After orthodontic aligning of the remaining teeth, a ridge build-up was performed with soft tissue augmentation alone, the pontic area conditioned with a removable partial denture, and a 4-unit adhesive pfm-bridge inserted, which serves also as a retainer in the upper jaw.

Gap distribution

Restorative compensation with direct composite restorations, etched pieces or porcelain veneers:

In Case 8 there is a Bolton-discrepancy, the anterior tooth forms of a young lady were restored using a direct approach with composite. Diagnostics include a direct mock-up with the respective composite, allowing to test both the correct layering to achieve the aspired colors and the optimal shape, and also to test whether this is realizable in the hands of the clinician. The mock-up is photographed and further analyzed. In addition, optical or analogue impressions can be taken for documentation, before the planned alterations are realized definitively with the direct composite technique. It can also be helpful during the orthodontic treatment to evaluate the aesthetic potential of the repositioned teeth by an interim mock-up.

Gap shifting.

Restorative compensation with all-ceramic adhesive bridges, composite, etched pieces or veneers:

This is an interesting alternative to avoid aesthetic problems in the zone of the most prominent aesthetic effects. Either a gap is shifted away from the aesthetic zone, or multiple gaps are reduced to one gap, and an additional front tooth is inserted with an all-ceramic adhesive bridge. Thus, multiple restorations or reconstructions to enlarge teeth that are too small can be avoided in favor of one single reconstruction on one single abutment tooth, be it a pontic or a veneer, or simple direct composites on the teeth adjacent to the opened gap.

Case 9 is an instructive example. The lower small front teeth which presented all gaps were grouped to one side, and a fifth front tooth was added adhesively with a bonded bridge. This is an elegant option for the lower front area, where 5 instead of 4 incisors are not obvious to the eye of the beholder.

Gap compensation

by reconstructive compensation without orthodontics

A case may not be indicated for a combined orthodontic-reconstructive approach, if major reconstructive interventions are needed anyway to compensate for missing or malformed tooth substance in a major amount. If still minimal invasive interventions are feasible, this can be an attractive option firstly to be efficient and effective, and secondly to avoid problems with the potential relapse after orthodontic treatment.

The patient - Case 10 - presented with a pronounced Bolton-discrepancy and an equally pronounced amelogenesis imperfecta. In view of the large amount of missing tooth structure, the patient was reconstructed in total by veneers with no to minimal preparations, all-ceramic partial crowns and adhesive full veneer crowns without orthodontic intervention. The lower very small teeth were enlarged with slightly overlapping shapes to hide the dimensions and achieve a believable appearance.

Final remarks

Adhesive dentistry today offers an outstanding potential to resolve also complex cases with minimally invasive techniques, be it direct or indirect. The high potential for reintervention places it at the premium position of restorative and reconstructive dentistry. This includes also the possibility for the patient to choose between different valuable and sustainable options for comparable clinical situations. However, in the light of the increasing complexity of optimally managing materials and techniques used in current restorative and reconstructive dentistry, the individual levels of knowledge and manual skills⁶¹ of the involved clinicians and dental technicians are the key factors for success.

Special thanks for their highly esteemed contributions go to the team partners who are involved in these cases: the dental technicians Nic Pietrobon & Reto Michel and Walter Gebhard, and Dr. Marco Tribo for the orthodontics and his expertise in the treatment plannings.

References

1. Bolton W,
Disharmony In Tooth Size And Its Relation To Treatment of Malocclusion
Angle Orthodontist. 1958
2. Marinello CP, Schärer P.
Single tooth replacement in young patients. The differential therapeutic considerations from the prosthetic viewpoint.
Schweiz Monatsschr Zahnmed. 1990;100(5):596-611
3. Marinello CP, Meyenberg KH, Zitzmann N, Lüthy H, Soom U, Imoberdorf M.
Single-tooth replacement: some clinical aspects.
J Esthet Dent. 1997;9(4):169-78.
4. Meyenberg KH, Imoberdorf MJ.
The aesthetic challenges of single tooth replacement: a comparison of treatment alternatives.
Pract Periodontics Aesthet Dent. 1997;9(7):727-35
5. Spear FM, Kokich VG, Mathews D
Pinterdisciplinary management of anterior dental esthetics.
J Am Dent Assoc. 2006 Feb;137(2):160-9.
6. Kokich VO Jr, Kinzer GA.
Managing congenitally missing lateral incisors. Part I: Canine substitution.
J Esthet Restor Dent. 2005;17(1):5-10.
7. Barrack G
Recent advances in etched cast restorations.
J Prosthet Dent. 1984 Nov;52(5):619-26.
8. Barrack G1, Bretz WA.
A long-term prospective study of the etched-cast restoration.
Int J Prosthodont. 1993 Sep-Oct;6(5):428-34.
9. Marinello CP, Kerschbaum T, Heinenberg B, Hinz R, Peters S, Pfeiffer P, Reppel PD, Schwickerath H.
First experiences with resin-bonded bridges and splints—a cross-sectional retrospective study, Part II.
J Oral Rehabil. 1988 May;15(3):223-35.
10. Marinello CP
Adhesive Reconstructions. Clinical and Technical Aspects
(Thesis) Quintessence Berlin 1991.
11. Kern, Matthias
RBFDPs - Resin-Bonded Fixed Dental Prostheses Minimally invasive - esthetic – reliable.
1st edition 2017 ISBN 978-1-78698-020-5. Quintessence Publishing, Deutschland.
12. Mourshed B, Samran A, Alfagih A, Samran A, Abdulrab S, Kern M.
Anterior Cantilever Resin-Bonded Fixed Dental Prostheses: A Review of the Literature.
J Prosthodont. 2018 Mar;27(3):266-275.
13. Kern M.
Clinical long-term survival of two-retainer and single-retainer all-ceramic resin-bonded fixed partial dentures.
Quintessence Int. 2005 Feb;36(2):141-7.
14. Kern M, Passia N, Sasse M, Yazigi C.
Ten-year outcome of zirconia ceramic cantilever resin-bonded fixed dental prostheses and the influence of the reasons for missing incisors.
J Dent. 2017 Oct;65:51-55.

15. Sailer I, Hämmerle CH.
Zirconia ceramic single-retainer resin-bonded fixed dental prostheses (RBFDPs) after 4 years of clinical service: a retrospective clinical and volumetric study.
Int J Periodontics Restorative Dent. 2014 May-Jun;34(3):333-43.
16. Sailer I, Bonani T, Brodbeck U, Hämmerle CH.
Retrospective clinical study of single-retainer cantilever anterior and posterior glass-ceramic resin-bonded fixed dental prostheses at a mean follow-up of 6 years.
Int J Prosthodont. 2013 Sep-Oct;26(5):443-50.
17. Zitzmann NU, Özcan M, Scherrer SS, Bühler JM, Weiger R, Krastl G.
Resin-bonded restorations: a strategy for managing anterior tooth loss in adolescence.
J Prosthet Dent. 2015 Apr;113(4):270-6.
18. Mahl D1, Marinello CP, Sendi P.
Markov models in dentistry: application to resin-bonded bridges and review of the literature.
Expert Rev Pharmacoecon Outcomes Res. 2012 Oct;12(5):623-9.
19. Goldstein RE.
Diagnostic dilemma: to bond, laminate, or crown?
Int J Periodontics Restorative Dent. 1987;7(5):8-29
20. Touati B, Plissart-Vanackere A.
Ceramic bonded veneers. Toward a minimal prosthesis.
Real Clin. 1990;1(1):51-66
21. Belser, U. C., Magne, P., & Magne, M.
Ceramic Laminate Veneers: Continuous Evolution of Indications.
Journal of Esthetic and Restorative Dentistry 1997, 9(4), 197–207.
22. Magne, Pascal / Belser, Urs C.
Bonded Porcelain Restorations in the Anterior Dentition A Biomimetic Approach
Quintessence Publishing, Deutschland 1st Edition 2002 ISBN 978-1-85097-183-2, ISBN 978-0-86715-422-1.
23. Gürel, Galip
The Science and Art of Porcelain Laminate Veneers
1st edition 2003 ISBN 978-1-85097-060-6 Quintessence Publishing, Deutschland
24. Fradeani M1, Redemagni M, Corrado M.
Porcelain laminate veneers: 6- to 12-year clinical evaluation—a retrospective study.
Int J Periodontics Restorative Dent. 2005 Feb;25(1):9-17.
25. Morimoto S, Albanesi RB, Sesma N, Agra CM, Braga MM
Main Clinical Outcomes of Feldspathic Porcelain and Glass-Ceramic Laminate Veneers: A Systematic Review and Meta-Analysis of Survival and Complication Rates.
Int J Prosthodont. 2016 Jan-Feb;29(1):38-49.
26. Hugo, Burkard
Esthetics with Resin Composite - Basics and Techniques.
1st Edition 2008 ISBN 978-1-85097-183-2. Quintessence Publishing, Deutschland.
27. Baratieri, Luiz Narciso / Monteiro Junior, Sylvio / Spezia de Melo, Tiago (Hrsg.)
Routes for Excellence in Restorative Dentistry Mastery for Beginners and Experts
1st edition 2015 ISBN 978-85-7889-039-1 Quintessence Publishing, Deutschland
28. Terry, Douglas A. / Geller, Willi.
Esthetic and Restorative Dentistry - Material Selection and Technique
3rd Edition 2018 Quintessence Publishing, USA ISBN 978-0-86715-763-5
29. Devoto W, Saracinelli M, Manauta J.
Composite in everyday practice: how to choose the right material and simplify application techniques in the anterior teeth.
Eur J Esthet Dent. 2010 Spring;5(1):102-24
30. Villarroel M, Fahl N, De Sousa AM, De Oliveira OB Jr
Direct esthetic restorations based on translucency and opacity of composite resins. J Esthet Restor Dent. 2011 Apr;23(2):73-87.
31. Dietschi D, Shahidi C, Krejci I.
Clinical performance of direct anterior composite restorations: a systematic literature review and critical appraisal.
Int J Esthet Dent. 2019;14(3):252-270
32. Liebler M1, Devigus A, Randall RC, Burke FJ, Pallesen U, Cerutti A, Putignano A, Cauchie D, Kanzler R, Koskinen KP, Skjerven H, Strand GV, Vermaas RW.
Ethics of esthetic dentistry.
Quintessence Int. 2004 Jun;35(6):456-65.

33. Nordquist GC, McNeill RW.
Orthodontic vs. restorative treatment of the congenitally absent lateral incisor - longterm periodontal and occlusal evaluation.
J Period 1975; 46: 139-43.
34. Senty EL. The maxillary cuspid and missing lateral incisors: Esthetics and occlusion.
Angle Orthod 1976; 46: 365-71.
35. Robertsson S, Mohlin B. The congenitally missing lateral incisor. A retrospective study of orthodontic space closure versus restorative. treatment.
Eur J Orthod 2000; 22: 697-710.
36. Marchi LM1, Pini NI, Hayacibara RM, Silva RS, Pascotto RC
Congenitally missing maxillary lateral incisors: functional and periodontal aspects in patients treated with implants or space closure and tooth re-contouring.
Open Dent J. 2012;6:248-54.
37. Elsayed A, Meyer G, Wille S, Kern M.
Influence of the yttrium content on the fracture strength of monolithic zirconia crowns after artificial aging.
Quintessence Int. 2019;50(5):344-348.
38. Camposilvan E, Leone R, Gremillard L, Sorrentino R, Zarone F, Ferrari M, Chevalier J. Aging resistance, mechanical properties and translucency of different yttria-stabilized zirconia ceramics for monolithic dental crown applications.
Dent Mater. 2018 Jun;34(6):879-890.
39. Shahmiri R, Standard OC, Hart JN, Sorrell CC.
Optical properties of zirconia ceramics for esthetic dental restorations: A systematic review.
J Prosthet Dent. 2018 Jan;119(1):36-46.
40. Kolakarnprasert N, Kaizer MR, Kim DK, Zhang Y.
New multi-layered zirconias: Composition, microstructure and translucency.
Dent Mater. 2019 May;35(5):797-806.
41. Guñh JF, Stawarczyk B, Edelhoff D, Liebermann A.
Zirconia and its novel compositions: What do clinicians need to know?
Quintessence Int. 2019;50(7):512-520.
42. Meng Z1, Yao XS, Yao H, Liang Y, Liu T, Li Y, Wang G, Lan S.
Measurement of the refractive index of human teeth by optical coherence tomography.
J Biomed Opt. 2009 May-Jun;14(3):034010.
43. Wood DL, Nassau K.
Refractive index of cubic zirconia stabilized with yttria.
Appl Opt. 1982 Aug 15;21(16):2978-81
44. Zhang Y1.
Making yttria-stabilized tetragonal zirconia translucent.
Dent Mater. 2014 Oct;30(10):1195-203.
45. Özcan M, Matinlinna J.
Surface Conditioning Protocol for the Adhesion of Resin-based Cements to Base and Noble Alloys: How to Condition and Why?
J Adhes Dent. 2015 Aug;17(4):372-3.
46. Cattani Lorente M, Scherrer SS, Richard J, Demellayer R, Amez-Droz M, Wiskott HW.
Surface roughness and EDS characterization of a Y-TZP dental ceramic treated with the CoJet™ Sand.
Dent Mater. 2010 Nov;26(11):1035-42.
47. Scherrer SS, Cattani-Lorente M, Vittecoq E, de Mestral F, Griggs JA, Wiskott HW.
Fatigue behavior in water of Y-TZP zirconia ceramics after abrasion with 30 µm silica-coated alumina particles.
Dent Mater. 2011 Feb;27(2):e28-42.
48. Kern M, Barloi A, Yang B.
Surface conditioning influences zirconia ceramic bonding.
J Dent Res. 2009 Sep;88(9):817-22.
49. Özcan M, Bernasconi M.
Adhesion to zirconia used for dental restorations: a systematic review and meta-analysis.
J Adhes Dent. 2015 Feb;17(1):7-26.
50. Kwon SJ1, Lawson NC2, McLaren EE3, Nejat AH4, Burgess JO5.
Comparison of the mechanical properties of translucent zirconia and lithium disilicate.
J Prosthet Dent. 2018 Jul;120(1):132-137.

51. Garber DA, Rosenberg ES.
Ovate Pontic Design: The edentulous ridge in fixed prosthodontics.
Compend Contin Educ Dent 1981;2:212-23.
52. Edelhoff D, Spiekermann H, Yildirim M.
A review of esthetic pontic design options.
Quintessence Int. 2002 Nov-Dec;33(10):736-46.
53. Zuhr, Otto, Hürzeler, Marc
Plastic-Esthetic Periodontal and Implant Surgery
ISBN 978-1-85097-294-5
Quintessence Publishing, Deutschland
54. Zitzmann NU1, Marinello CP, Berglundh T.
The ovate pontic design: a histologic observation in humans.
J Prosthet Dent. 2002 Oct;88(4):375-80.
55. Elsayed A, Younes F, Lehmann F, Kern M.
Tensile Bond Strength of So-called Universal Primers and Universal Multimode Adhesives to Zirconia and Lithium Disilicate Ceramics.
J Adhes Dent. 2017;19(3):221-228.
56. Maier E, Bordihn V, Belli R, Taschner M, Petschelt A, Lohbauer U, Zorzin J.
New Approaches in Bonding to Glass-Ceramic: Self-Etch Glass-Ceramic Primer and Universal Adhesives.
J Adhes Dent. 2019;21(3):209-217.
57. Kern M1, Neikes MJ, Strub JR.
Optimizing the bond between metal and bonding agent in bonded restorations using a simplified silicoating procedure.
Dtsch Zahnärztl Z. 1990 Aug;45(8):502-5.
58. Kern M, Thompson VP. Sandblasting and silica-coating of dental alloys: volume loss, morphology and changes in the surface composition.
Dent Mater. 1993 May;9(3):151-61.
59. Robin C, Scherrer SS, Wiskott HW, de Rijk WG, Belsler UC.
Weibull parameters of composite resin bond strengths to porcelain and noble alloy using the Rocatec system.
Dent Mater. 2002 Jul;18(5):389-95.
60. Yanagida H1, Tanoue N, Ide T, Matsumura H.
Evaluation of two dual-functional primers and a tribochemical surface modification system applied to the bonding of an indirect composite resin to metals.
Odontology. 2009 Jul;97(2):103-8.
61. Demarco FF, Collares K, Correa MB, Cenci MS, Moraes RR, Opdam NJ
Should my composite restorations last forever? Why are they failing?
Braz Oral Res. 2017 Aug 28;31

Discussion (45 min)

The recorded discussion aims to be published. It should be organized in a constructive way by the Moderator. The discussion ideally will reach an outcome of consensus conclusions.

Essayist IV

Dr. Roberto Cocchetto:

On-going alveolar growth, continuous tooth eruption and implants.

Literature/Evidence – Clinical interpretation.

Introduction

The replacement of anterior missing teeth (either due to agenesis, or severe dental pathologies or trauma) has always been a challenge for Dentistry. For a long time, the only options available were removable appliances, too often offering poor functional and esthetic outcomes, or crown and bridges, inevitably too much demolitive in case of intact abutment teeth. Then the discovery and evolution of dental adhesion offered a better alternative, a resin-bonded prosthesis, the Maryland bridge, more efficient although often considered only a temporary solution.

After the advent of modern implantology the use of artificial roots to replace anterior missing teeth has become rapidly the preferred choice among patients and clinicians, being considered more “natural” than a traditional crown and bridge restoration and more functionally reliable than an adhesive bridge. But, as demonstrated in animal studies¹, a dental implant has an ankyrotic connection with the bone and does not follow the natural eruption of the adjacent teeth and so the implant-supported crown remains

stationary while the surrounding alveolar bone and teeth will “move” mostly in forward and downward direction in the anterior maxilla. This is in analogy to what happens when in children and adolescents a traumatically avulsed front tooth is re-implanted too late and becomes ankylotic to the bone, showing soon a progressive infra-occlusion which in time becomes an increasingly severe esthetic problem. Therefore, it is commonly recommended to delay implant placement until the alveolar growth has ceased, at the end of adolescence.

The purpose of this brief essay is to demonstrate, based on scientific literature and clinical evidence, that the infra-occlusion of anterior implant supported teeth (together with other related alterations) may happen also in a large number of adult patients (Fig.1), affecting the long-term results of implant treatment, sometimes in a severe manner (Fig.2). Considering that more than two thirds of dental implants are inserted in the anterior maxilla² it is important to improve our knowledge of this topic and review our concepts in treatment planning anterior missing teeth replacement.

Literature evidence

It is quite surprising that this complication of implant treatment, far from being rare, is very little known within the dental community. Even more surprising is the fact that the term “infraocclusion” associated to dental implants cannot be found in the latest edition of the Glossary of terms sponsored by the world main scientific organizations dedicated to implantology, (AAO and EAO), as it is in other similar publications. Moreover, only in the latest edition of the most comprehensive textbook on complications in implant dentistry³, a new chapter has been included: “Craniofacial growth in adults and its implications for implant reconstruction”. And again, recently, a detailed paper⁴, analyzing 50 years of osseointegration from different perspectives did not mention at all this problem even among the “final open questions”.

It appears therefore necessary to review the literature on the topic but first it can be useful to briefly resume some basic knowledge on craniofacial growth which is indeed a very complex topic. Beyond sutural growth which is responsible of most of cranial development, facial growth happens through apposition and resorption of maxilla and mandible (the latter also from condylar growth). Donald Enlow's “V” Principle postulates that the bones of the craniofacial area which have a V shape configuration show bone resorption happening on the outer side of the “V” of the bone while bone deposition happens on the inner side of the “V”. Therefore, the movement of bone during growth happens towards the open-end of the V. Then, to accommodate tooth eruption, maxilla and mandible grow together in a downward and forward direction (Counterpart Principle)⁵.

It is a common knowledge that the growth of the bones supporting the dentition is increasing from childhood to adolescence and then decreases and almost completely stops with the cessation of skeletal growth. For this reason, it has been suggested that, when indicated, implants should be placed only after the age when skeletal growth is thought to be completed^{6,7,8,9}. The end of adolescence and the beginning of adulthood coincides with the exhaustion of growth potential, but adaptive changes of the jaws continue. The amount of growth decreases steadily after the second decade of life but some studies in the orthodontic literature, indicate that growth of facial skeleton continues throughout life, progressing in a time-span of over sixty years^{10,11,12,13,14,15}. In particular, it has been demonstrated that maxillary teeth eruption does not stop after skeletal maturation. While the anterior maxilla of male patient remains straight, female show a tendency of the incisors to incline their apex in palatal direction. Males are “forward rotators” and female are more “backward rotators”. Also, posterior teeth, molars and premolars, tend to erupt, even at a lesser extent than canines and incisors and so, a posterior implant crown may also become infraoccluded¹⁶.

In the vertical dimension average changes are small, but with a large interindividual variability, so that some patients showing maximum growth may show 2 to 3 mm of vertical increase in the natural teeth and a corresponding infraocclusion of the implant crown, while others, with little or no growth, show no vertical change and no infraocclusion⁶. Less relevant modifications take place in arch dimensions. For example, the maxillary intercanine width is thought to increase significantly up to approximately 16 years of age¹⁴ and then tends to decrease a little, no more than 0.5 to 1.0 mm over a 20-year span. Nevertheless, there are some clinical cases which contradicts this fact and show, for example, the progressive formation of a diastema between a central incisor implant supported crown and the adjacent lateral incisor. In a similar case reported in a recent paper¹⁷, at a later stage, the implant-supported crown developed also infraocclusion, together with a further increase of the diastema.

Because of the effects of all the above subtle but continuous modifications taking place in a large number of adult implant patients, there has been a growing number of clinical observations and some articles began to appear also in the dental implant literature, mostly retrospective analysis of the outcome of implants placed in the anterior maxilla of adult patients. In order to draw a short summary of

the results reported by these publications, it can be useful to analyze some parameters that may be relevant in the interpretation of the infraocclusion phenomenon.

First of all the frequency of infraocclusion varies in different studies from a minimum of 40%¹⁸ to 100%¹⁹ of the cases. In regard to patient's age as a predisposing factor, only one study²⁰ reported a three times greater probability of infraocclusion for patients under 30 years, while others^{18,19,21,22,23} did not find differences.

As for sex as a predisposing factor, one author²⁴ reported that females had a significantly greater chance than males to develop infraocclusion, but the sample size was limited to 28 crowns (20 in males, 8 in females). All the other studies found no difference^{18,19,21,22,23}.

Patients showing an anatomic pattern defined as the Long Face syndrome were considered at higher risk²⁵, but only an article found a weak association with infraocclusion¹⁸. Moreover, Aarts et al.²⁶ demonstrated that facial growth cessation is not influenced by the shape of the face.

Another possible contributing factor is the state of occlusion, namely a lack of occlusal contacts of the anterior maxilla, but in only one study²⁷ conducted on a small group of 10 adolescents (15-19 years) a correlation was suggested. On the contrary, the lack of posterior occlusal contact, when there are posterior free-end implant restorations in both arches, if they become infraoccluded the loss of their bearing capacity can put under stress the remaining anterior dentition with mechanical consequences²⁸. At the moment there is the only one very recent publication with a prospective design²⁹. 31 patients (18 women and 13 men, with a mean and median age of 23.8 and 18.8 years, range 17.8 to 52.8 years) received single anterior maxillary implants. A slight (< 0.5 mm). Infra-position was found in 36% of cases but with a mean follow-up of only 4.5 years (range 3.3 to 6.6).

For the sake of completeness, another clinical consequence of the ongoing adult facial growth must be mentioned: the interproximal contact loss (ICL), namely the formation of a space, usually between the mesial aspect of an implant supported crown and the adjacent tooth (Fig.3). The frequency of this complication which is related to the spontaneous mesial drift of teeth, generating anterior crowding in the maxilla but mostly in the mandible, ranges from 34% to 66% and is more precocious and more disturbing for the patient than infraocclusion, generating problems like food impaction, caries and peri-implant mucositis.³⁰ A recent extensive retrospective study³¹ on 4325 implants reported a much lower incidence (17%) of ICL, although increasing over time (28% at 8 years). No difference was found between males and females. The possible role of occlusal forces as a contributing factor has been dismissed.

Clinical interpretation

From the above synthetic analysis of the scarce literature available, it appears that the only proven fact is the relevant incidence of the on-going modifications of jaws in adult implant patients. So how is that the topic is still rarely included in the program of scientific meetings and it is unknown to a large majority of dentists? The simple answer is that these modifications need years to take place, at least 3 to 5, but with a large interindividual variability and also with some notable exceptions. An example is the case of a 35-year-old female patient whose upper left central incisor supported by an implant, developed a remarkable infra-occlusion of 1.2 mm in only 15 months³²(Fig.4).

Basically, most of the patients with infra-occlusion (and also many dentists) do not notice this initial minimal discrepancy and if they do, in the majority of cases they tend to disregard it. In a recent article²³ the patient's "awareness and perception" of the problem has been analyzed through a questionnaire which produced a score for each patient. As expected, most of the patients with infra-occlusion (71.8%) either failed to notice or to consider it as an esthetic problem, but 18.2% of them expressly requested to be treated. In particular female patients requesting treatment were 22.2%. Four out of six of them presented a high smile line, so that the more apical gingival margin, very often associated to the infraoccluded crowns, increased the negative esthetic effect of the incisal margin discrepancy.

It is true that in many cases the esthetic problem generated by infra-occlusion can be easily solved, i.e. elongating the incisal margin or making a new crown if needed. Therefore, the implant prosthetic design should be planned to facilitate crown retrievability. Screw retention must be preferred and if a cement retained crown is used, a low adhesion luting material is indicated. Patient's age at time of implant insertion has not been confirmed as a contributing factor for infraocclusion. Nevertheless, if a patient is in the first half of the third decade and later develops infraocclusion needing a first corrective intervention, it must be expected that, as reported in the literature,³³ infraocclusion will probably emerge again at a later time. This may well enough become a reason to maintain as much as possible natural abutments before declaring a tooth hopeless and candidate for extraction, as too often happens.

It makes sense to delay, if possible, the use of implants in the esthetic zone in young adults, because implants are not always the best solution to replace some missing teeth. Moreover, it is important to bear in mind that in some cases the result of infraocclusion can be severely disfiguring and require very complex and invasive treatments, like surgical implant repositioning by segmental osteotomy combined with osseodistraction, or submergence or removal of the implant.³⁴ If more than one adjacent implant is involved the treatment may become very difficult and its outcome unpredictable. For these reasons, especially when replacing an anterior tooth, alternative treatment options must be considered and discussed with the patients. For example, traditional crown-and-bridge offers a well-documented long-term efficacy and should be considered the first choice when the teeth adjacent to the edentulous site are already prosthetically restored. In case of intact dentition, resin-bonded fixed restorations have, in recent years, improved very much their functional and esthetic performance.³⁵

It is advisable to apply a Patient-Reported Outcome Measures (PROMs) approach also to this specific area of treatment, as it has been suggested for other fields of implant dentistry³⁶. Finally, when the implant option has been chosen it is mandatory to thoroughly explain to the patient that the restoration might need to be modified in the future to adapt it to possible subtle anatomical changes whose development and amount cannot be anticipated. This should be included in the informed consent form, to be signed by the patient. It is equally important to define the liability issue, when different professionals are involved in the treatment (oral surgeon, periodontist, prosthodontist) in order to avoid future legal disputes. Future well designed studies (i.e. prospective ones) are necessary to improve our knowledge of this relevant aspect of implant treatment.

Conclusions

1. Adult craniofacial growth is a proven clinical fact.
2. It may become a problem when implants are placed within the natural dentition.
3. Infraocclusion and interproximal contact loss are the more common complications.
4. The majority of clinically significant cases are located in the maxillary esthetic zone.
5. It evolves very slowly in time but with large variability in onset, progression and extent.
6. It has been weakly associated with female sex and Long Face skeletal types.
7. Clinical relevance is mostly minimal, but in some cases serious esthetic problems may arise.
8. It should be better studied and considered with attention in treatment planning the esthetic zone.
9. Alternative and predictable treatment modalities should also be reconsidered.
10. Patient's information is mandatory while medico-legal liability issues need to be clarified.

References

1. Sennerby L, Odman J, Lekholm U, Thilander B.
Tissue reactions towards titanium implants inserted in growing jaws. A histological study in the pig.
Clin Oral Impl Res 1993; 4: 65-75
2. Andersson B, Odman P, Carlsson GE.
A study of 184 consecutive patients referred for single-tooth replacement.
Clin Oral Implants Res 1995; 6:232-237.
3. Froum SJ, (editor)
Dental Implant Complications. Etiology, Prevention and Treatment
Hoboken, Wiley-Blackwell Editions, 2015
4. Buser D, Sennerby L, De Bruyn H.
Modern implant dentistry based on osseointegration: 50 years of progress, current trends and open questions.
Periodontol 2000. 2017 Feb;73(1):7-21.
5. Henlow D, Hans M
Essentials of Facial Growth.
Philadelphia, W. B. Saunders Company, 1996.
6. Oesterle L, Cronin R.
Adult growth, aging and the single tooth implant
Int J Oral Maxillofac Implants 2003; 15: 252-260
7. Fudalej P, Kokich VG, Leroux B.
Determining the cessation of vertical growth of the craniofacial structures to facilitate placement of single-tooth implants.
Am J Orthod Dentofac Ortho 2007; 131 (4 Suppl): 59-67.
8. Bergendhal B.
When should we extract deciduous teeth and place implants in young individuals with tooth agenesis?
J Oral Rehab 2008; 35 (Suppl 1): 55-63.

9. Carmichael RP, Sandor GK.
Dental implants, growth of the jaws, and determination of skeletal maturity.
Atlas Oral Maxillofac Surg Clin North Am 2008; 16: 1-9
10. Björk A, Skieller V.
Postnatal Growth and Development of the Maxillary Complex, monograph 6,
Craniofacial Growth Series. Ann Arbor, MI: Univ of Michigan Press, 1976:61-99
11. Forsberg CM.
Facial morphology and aging: a longitudinal cephalometric investigation of young adults.
Eur J Ortho 1979; 1: 15-23
12. Behrents RG.
The biological basis for understanding craniofacial growth during adulthood.
Prog Clin Biol Res 1985; 187: 307-19
13. Korn EL, Baumrind S.
Transverse development of the human jaws between ages of 8.5 and 15.5 years, studied longitudinally with the use of implants.
J Dent Res 1990; 69: 1298-1306
14. Bishara SE, Treder JE, Damon P, Olsen M.
Changes in the dental arches and dentition between 25 and 45 years of age.
Ang Ortho 1996; 66: 417-422
15. Iseri H, Solow B.
Continued eruption of maxillary incisors and first molars in girls from 9 to 25 years, studied by the implant method. *Eur J Ortho* 1996; 18, 245-56
16. West KS, McNamara JA.
Changes in the craniofacial complex from adolescence to mid-adulthood: a cephalometric study.
Am J Ortho Dentofac Orthoped 1999; 115: 521-532.2.
17. Kritzler K, Kritzler U, Cocchetto R, Bartzela T
Damned if we do and Damned if we don't. Adverse Effects of Implants in the Combined Orthodontic-Restorative Treatment of Maxillary Lateral Incisor Agenesis. Review of an Esthetic Dilemma.
Submitted for publication
18. Andersson B, Bergenblock S, Furst B, Jemt T.
Long-term function of single-implant restorations: a 17- to 19-year follow-up study on implant infraposition related to the shape of the face and patients' satisfaction.
Clin Impl Dent Rel Res 2013; 15: 471-480
19. Bernard JP, Schatz JP, Christou P, Belser U Kiliaridis S.
Long-term vertical changes of the anterior maxillary teeth adjacent to single implants in young and mature adults. A retrospective study.
J Clin Perio 2004; 31: 1024-8 34
20. Schwartz-Arad D, Bichacho N.
Effect of Age on Single Implant Submersion Rate in the Central Maxillary Incisor Region: A Long-Term Retrospective Study.
Clin Impl Dent Rel Res 2015; 17: 509-514
21. Chang M, Wennstrom J
Longitudinal changes in tooth/single implant relationship and bone topography: an 8-year retrospective analysis.
Clin Impl Dent Rel Res 2012; 14: 388-394.
22. Dierens M, De Bruecker E, Vandeweghe S, Kisch J, De Bruyn H, Cosyn J.
Alterations in soft tissue levels and aesthetics over a 16 to 22-year period following single implant treatment in periodontally-healthy patients: a retrospective case series.
J Clin Perio 2013; 40: 311-318
23. Cocchetto R, Pradies G, Celletti R, Canullo L
Continuous craniofacial growth in adult patients treated with dental implants in the anterior maxilla
Clin Implant Dent Relat Res. 2019 Apr 29. doi: 10.1111/cid.12790. [Epub ahead of print]
24. Jemt T, Ahlberg G, Henriksson K, Bondevik O.
Tooth movements adjacent to single-implant restorations after more than 15 years of follow-up.
Int J Prosth 2007; 20: 626-3237. 38.
25. Op Heij, D.G., Opdebeeck, H., van Steenberghe, D., Kokich, V.G., Belser, U. & Quirynen, M.
Facial development, continuous tooth eruption, and mesial drift as compromising factors for implant placement.
Int J Oral Maxillofac Implants 2006; 21: 867-878.

26. Aarts, B., Convens, J., Bronkhorst, E., Kuijpers-Jagtman, A. & Fudalej, P.
Cessation of facial growth in subjects with short, average, and long facial types - implications for the timing of implant placement.
Journal of Craniomaxillofacial Surgery 2015; 43: 2106-2111
27. Thilander B, Odman J, Jemt T.
Single implants in the upper incisor region and their relationship to the adjacent teeth. An 8-year follow-up study.
Clin Oral Implants Res. 1999 Oct;10(5):346-55
28. Daftary F, Mahallati, R, Bahat O, Sullivan RM.
Lifelong craniofacial growth and their implications for osseointegrated implants.
Int J Oral Maxillofac Implants 2013; 28: 163-169.
29. Nilsson A, Johansson LÅ, Stenport VF, Wennerberg A, Ekfeldt A.
Infraposition of anterior maxillary implant-supported single-tooth restorations in adolescent and adult patients-A prospective follow-up study up to 6 years.
Clin Implant Dent Relat Res. 2019 Aug 5. doi: 10.1111/cid.12818. [Epub ahead of print]
30. Greenstein G, Carpentieri J, Cavallaro J.
Open contacts adjacent to dental implant restorations: Etiology, incidence, consequences, and correction: literature review
J Am Dent Assoc. 2016 Jan;147(1):28-34.
31. French D, Naito M, Linke B.
Interproximal contact loss in a retrospective cross-sectional study of 4325 implants: Distribution and incidence and the effect on bone loss and peri-implant soft tissue
J Prosthet Dent. 2019 Mar 15. j.prosdent.2018.11.011. [Epub ahead of print]
32. Cocchetto, R., Canullo, L. Celletti, R.
Infraposition of an implant retained maxillary incisor crown placed in an adult patient.
Int J Oral Maxillofac Implants 2018;33(4): e107-e111
33. Jemt T
Measurements of tooth movements in relation to single-implant restorations during 16 years: A case report.
Clin Implant Dent Relat Res. 2005;7(4):200-8.
34. Zitzmann NU, Arnold D, Ball J, Brusco D, Triaca A, Verna C.
Treatment strategies for infraoccluded dental implants.
J Prosthet Dent. 2015 Mar;113(3):169-74.
35. Sasse M, Kern M.
Survival of anterior cantilevered all-ceramic resin-bonded fixed dental prostheses made from zirconia ceramic.
J Dent. 2014 Jun;42(6):660-3.
36. De Bruyn H, Raes S, Matthys C, Cosyn J.
The current use of patient-centered/reported outcomes in implant dentistry: a systematic review.
Clin Oral Implants Res. 2015 Sep;26 Suppl 11:45-56

Figures and legends

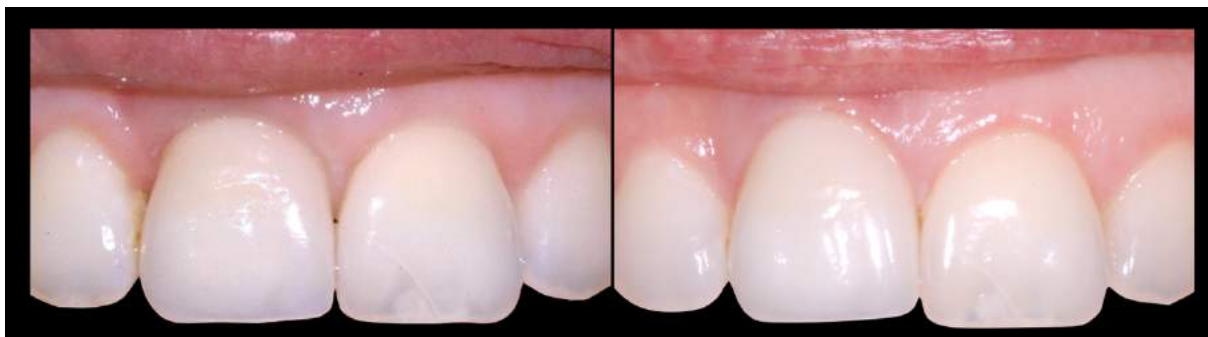

Fig.1: 28 years old female patient with one implant-supported crown in position n.11 (left) and 5 years later (right)

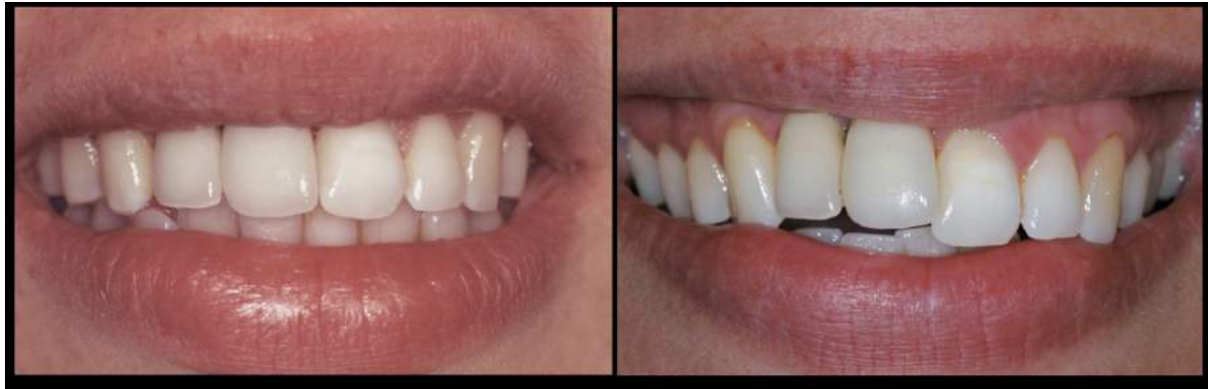

Fig. 2: 32 years old female patient with two implant-supported crowns in position 12-11 (left) and 12 years later.

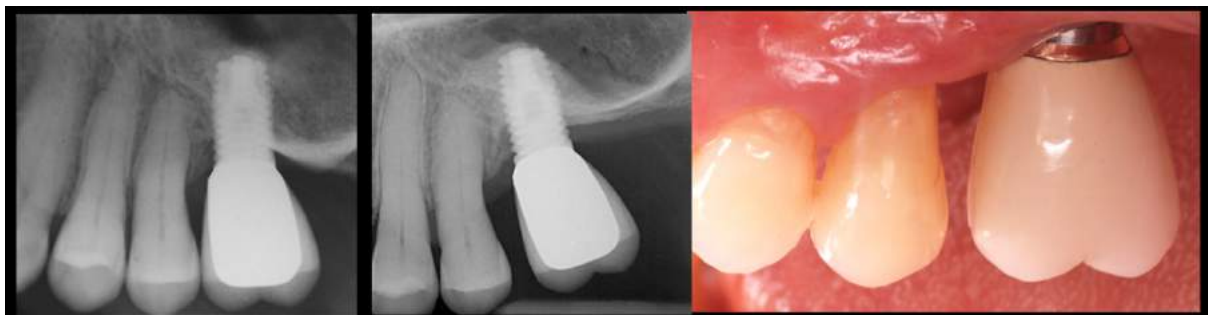


Fig. 3: Interproximal contact loss. X-ray of implant crown in position 26 (left) and 13 years later (center-right).

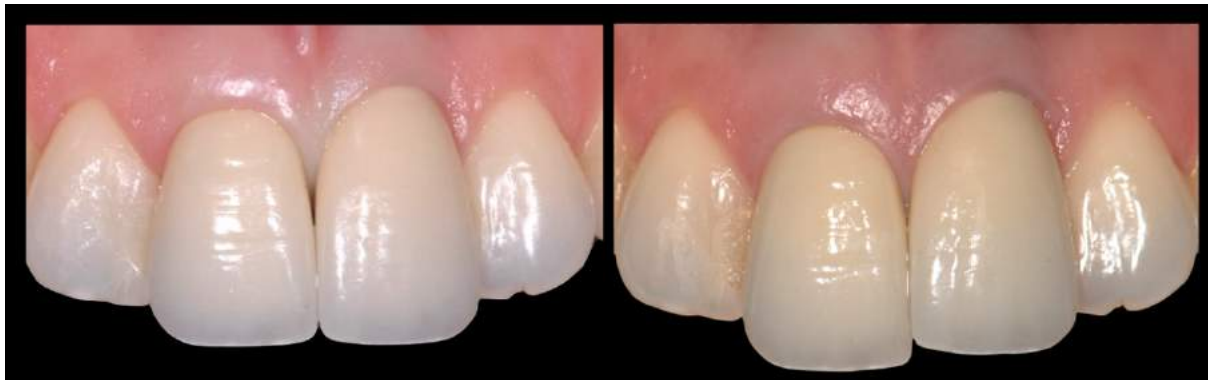

Fig. 4: 35 years old female patient with one implant-supported crown in position n. 21 (left) and 15 months later (right).

Discussion (45 min)

The recorded discussion aims to be published. It should be organized in a constructive way by the Moderator. The discussion ideally will reach an outcome of consensus conclusions.